

Totally Extra-Peritoneal (TEP) Laparoscopic Ventral Hernia and Incisional Hernia Repair: Reverse TEP (R-TEP)

Danilo C^{1*} and Silvana L²

¹Department of General Surgery and Surgical Pathology, Madre Teresa of Calcutta Hospital, Schiavonia, Padova, Italy

²Department of General Surgery and Surgical Pathology, Carlo Urbani Hospital, Jesi, Ancona, Italy

Volume 2 Issue 1 - 2019

Received Date: 03 Mar 2019

Accepted Date: 15 Mar 2019

Published Date: 21 Mar 2019

2. Keywords

Laparoscopic ventral hernia;
Reverse TEP

1. Abstract

Laparoscopic ventral hernia and incisional hernia repair has now become a standard technique. However, the disadvantage of this technique is the contact between the mesh and tacks and the viscera. The objective of this article is to describe totally laparoscopic extra-peritoneal ventral and incisional hernia repair to avoid this problem. We developed a reverse Dulucq's technique for laparoscopic inguinal hernia repair described as Reverse Totally Laparoscopic Extra-Peritoneal ventral hernia repair (R-TEP).

3. Introduction

Laparoscopic ventral hernia and incisional hernia repair has now become a standard technique. However, contact between mesh and tacks with the viscera is a disadvantage of this technique. Dulucq et al. [1] describes totally laparoscopic extra-peritoneal inguinal hernia repair (Dulucq's technique). Based on this innovative method, we describe a modified Dulucq's technique to apply to ventral and incisional hernia repair proposing the totally laparoscopic extra-peritoneal ventral and incisional hernia repair to avoid this problem [1]. We describe a reverse Dulucq's technique called Reverse Totally Laparoscopic Extra-Peritoneal ventral hernia repair (R-TEP).

4. Technique

The patient is in French position with legs apart and an extended left arm. The shoulder protection and bladder catheter are positioned. The operative field is prepared by leaving all of the abdomen uncovered from the pubic region to the ribs. The operator is between the legs, and the helping operator is indifferently to the right or to the left. The Veress needle is placed in the suprapubic region in Bogros' Space insufflating CO₂ of only 10 mmHg. Hasson positioning in the supra pubic region with an open or blind technique changing CO₂ to 12 mmHg. It is accessed in Bogros' space already insufflated with 30 degrees optic. Smooth medial dissection only with the same optic device in order to place two more trocars in the right and in the left inguinal region. The dissection continues beyond Douglas' arch

with the monopolar or bipolar device. Continuing first laterally to the right and left of the umbilicus under the rectus muscles just to the ribs unlike TEP: Reverse TEP. The hernia is left to the last dissection. After having formed the pre-peritoneal space by equalizing the epigastric vessels and the rectus muscles, applying blunt dissection to the ventral or incisional hernia without opening the peritoneum. Accurate revision of haemostasis. Reducing CO₂ to 8 mmHg. The mesh is placed on the hernia defect with or without tacks. Reducing CO₂ to zero mmHg leaving the posterior fascia and peritoneum to compress the mesh under the rectus muscles. [Figure 1 - 3]

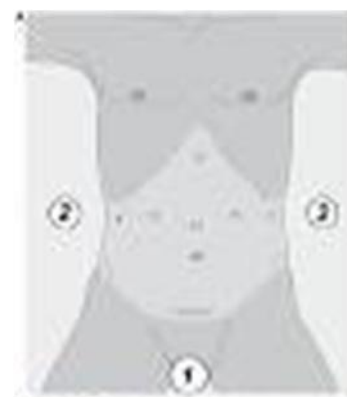

Figure 1: The mesh is placed on the hernia defect with or without tacks. Reducing CO₂ to zero mmHg leaving the posterior fascia and peritoneum to compress the mesh under the rectus muscles.

*Corresponding Author(s): Danilo Coco MD, Department of General Surgery and Surgical Pathology, Madre Teresa of Calcutta Hospital, Schiavonia, Padova, Italy, E-mail: webcostruction@msn.com

Citation: Danilo C, Silvana L, Totally Extra-Peritoneal (T.E.P.) Laparoscopic Ventral Hernia and Incisional Hernia Repair: Reverse T.E.P. (R-TEP). Annals of Clinical and Medical Case Reports. 2019;2(1):1-2.

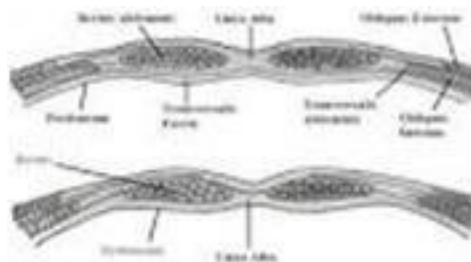


Figure 2: The mesh is placed on the hernia defect with or without tacks. Reducing CO₂ to zero mmHg leaving the posterior fascia and peritoneum to compress the mesh under the rectus muscles.

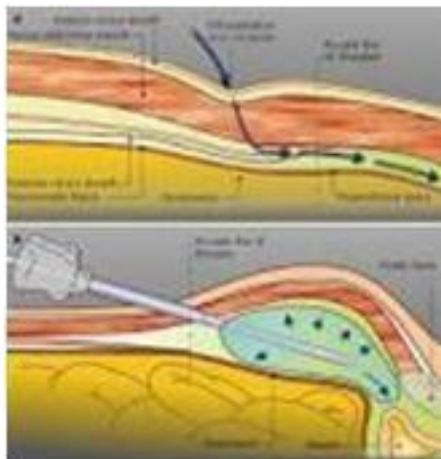


Figure 3: The mesh is placed on the hernia defect with or without tacks. Reducing CO₂ to zero mmHg leaving the posterior fascia and peritoneum to compress the mesh under the rectus muscles.

5. Discussion

The Reverse TEP is a technique that is inspired by Dulucq's technique for extra peritoneal inguinal hernia repair. However, it is not from the umbilicus to the inguinal region and pubic region but extends from these areas to the ribs. It permits wall dissection without passing through the abdomen. In this way, we avoid injuries of the intestinal loop, bleeding of the omentum in the hernia, postoperative ileus and unnecessary viscerolysis passing from an untrained space. Another significant advantage is that of having a totally extra peritoneal mesh, which avoids mesh and tack contact with the viscera. Mesh and tacks are totally covered by peritoneum. The disadvantages are represented by the difficulty in learning the technique and finding the right Bogros' space, the increase in operating times and above all, by the difficulty in dissecting the region of the hernia defect if this one is not automatically reduced with CO₂. The risks are intestinal lesions and intra peritoneal invisible bleeding. For these reasons, we recommend an advanced skill in laparoscopic techniques and to have previously performed Trans-Abdominal-Pre-Peritoneal hernia repair (TAPP) or Totally Extra-Peritoneal (TEP) in order to be extremely familiar with the extra peritoneal space [2,3]. We recommend the help of a tutor and an abdominal trocar placement to follow extra peritoneal dissection for the beginners in this technique. Reverse TEP is an excellent method that needs further comparative tests.

Reference

1. Meyer A, Dulucq JL, Mahajna A. Laparoscopic totally extraperitoneal hernioplasty with nonfixation of three-dimensional mesh: Dulucq's technique. *Arq Bras Cir Dig.* 2013; 26(1): 59 - 61
2. Bamba R, Wolfson J, Bhanot P. A Laparoscopic extraperitoneal approach to an incisional and inguinal hernia repair: A Case Report. *SM Surgery Journal.* 2015; 1(1): 1001.
3. Wake BL, McCormack K, Fraser C, Vale L, Perez J, Grant A. Two different laparoscopic techniques for repairing a hernia in the groin. *The Cochrane Library.* 2005.