

## Angiosarcoma like Squamous Cell Carcinoma of the Oral Cavity— Report of Rare Subtype of Squamous Cell Carcinoma

James S<sup>1</sup>, Aravind S<sup>2</sup> and Nayanar KS<sup>3</sup>

<sup>1</sup>Department of pathology, Fellow in Head and Neck pathology, Malabar cancer centre, Thalassery, Kannur, Kerala, India

<sup>2</sup>Department of pathology, Associate Professor, Malabar cancer centre, Thalassery, Kannur, Kerala, India

<sup>3</sup>Department of pathology, Prof & HOD, Malabar cancer centre, Thalassery, Kannur, Kerala, India

Volume 4 Issue 3- 2020

Received Date: 07 May 2020

Accepted Date: 27 May 2020

Published Date: 08 June 2020

### 2. Key words

Pseudovascular; Adenoid; Acantholytic;  
Angiosarcoma; Lower alveolus

### 1. Abstract

Acantholytic Squamous Cell Carcinoma (SCC) of the oral cavity is an uncommon but well recognized variant of SCC and angiosarcoma like SCC is a rarer subtype of this variant. Angiosarcoma like SCC has been reported to originate in the sun exposed skin of the head and neck region. Although rare, there are cases in records which are reported within the oral cavity. Histologically the lesion shows areas of conventional squamous cell carcinoma along with atypical epithelial cells forming an adenoid pattern which undergo pseudovascular changes mimicking angiosarcoma. There are insufficient reported cases to establish the likely behavior. Here we report a case of the same in view of its rarity.

### 3. Introduction or Background

International Agency of Research on Cancer (IARC) has classified variants of SCC into 7 types, namely, Acantholytic SCC, Adenosquamous carcinoma, Basaloid SCC, Carcinoma cuniculatum, Papillary carcinoma, Verrucous carcinoma, and Spindle cell carcinoma [1]. Adenoid SCC, also called as Acantholytic SCC is an uncommon histopathological variant of SCC characterized by acantholysis of the tumour cells, creating pseudo-lumina and appearance of glandular differentiation [2, 3]. Rarely, acantholysis may lead to the formation of anastomosing spaces and channels, resembling a vascular neoplasm. And this rare sub variant is called Pseudo-vascular/ Pseudo-angiomatous /Angiosarcoma like Squamous cell carcinoma (PASCC). This variant of SCC has been reported in the skin of the head and neck, as well as in other organs, such as the breast and lungs, urinary bladder, vulva and uterine cervix<sup>3</sup>. Only three cases of PASCC arising from the upper aero-digestive tract have been reported so far [4]. And we report this case in view of its rarity.

### 4. Case Presentation

A 46-year-old woman presented with a fast-growing ulcero-indurated lesion on the right lower alveolus in the last 6 months. She did not give any history of habits. On clinical examination, patient was moderately built and nourished. An ulcero-proliferative growth was seen over right buccal gingiva extending to lingual alveolar mucosa, measuring 2.5x2.5x0.8 cm in size. Incisional biopsy showed moderately differentiated SCC. We received a specimen of right marginal mandibulectomy and radical neck dissection.

Grossly, tumor abuts the mandible, overlying skin is not involved.

On microscopic examination, a markedly dysplastic stratified squamous epithelium lined tissue with an invasive neoplasm composed of cells arranged in nests and islands were seen (Figure 1). Tumor cells show acantholysis with pseudo lumina formation (Figure 2). Lumen of pseudoglandular spaces contained RBCs. Detached dyskeratotic acantholytic dysplastic cells were seen. Extensive areas with anastomosing spaces and channels lined by single layer of atypical epitheloid cells noted (Figure 3). A few cells showed suspicious intracytoplasmic lumen formation with entrapped RBC (Figure 4). A provisional differential diagnosis of acantholytic squamous cell carcinoma and angiosarcoma was made. IHC(Immunohistochemistry) panel on P63, P40, CD34, Fli1 and CD31 was run (Figure 5-9). P63 and P40 came out to be diffusely positive in tumour cells. CD31 was negative ruling out angiosarcoma. A final diagnosis of squamous cell carcinoma - pseudo angiosarcomatous variant (angiosarcoma like SCC) was made.

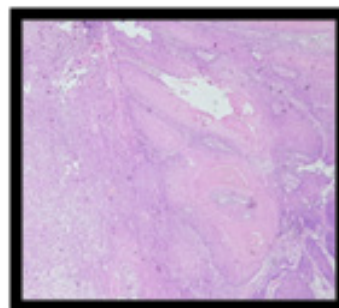


Figure 1: Invasive neoplasm composed of cells arranged in nests and islands

Citation: James S, Angiosarcoma like Squamous Cell Carcinoma of the Oral Cavity— Report of Rare Subtype of Squamous Cell Carcinoma. Annals of Clinical and Medical Case Reports. 2020; 4(3): 1-3.

\*Corresponding Author (s): Sherin James, Department of pathology, Fellow in head and neck pathology, Malabar cancer centre, Thalassery, Kannur, Kerala, India, Tel: 09496281799, E-Mail: sherinjames@gmail.com

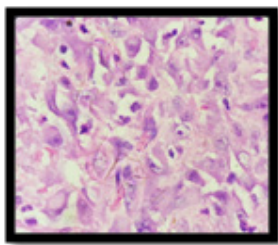


Figure 2: Tumor cells show acantholysis with pseudo lumina formation.

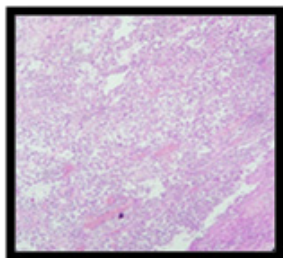


Figure 3: anastomosing spaces and channels lined by single layer of atypical epithelioid cells.

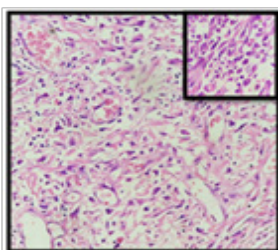


Figure 4: A few cells showed suspicious intracytoplasmic lumen formation.

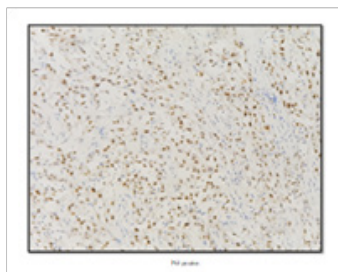


Figure 5: P63




Figure 6: P40

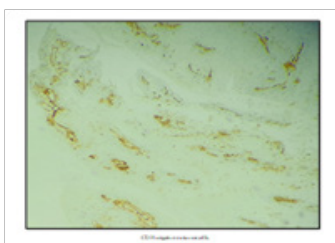


Figure 7: CD31 was negative ruling out angiosarcoma.

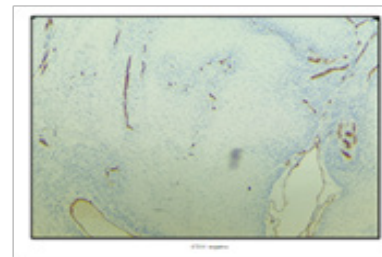


Figure 8: CD34 negative

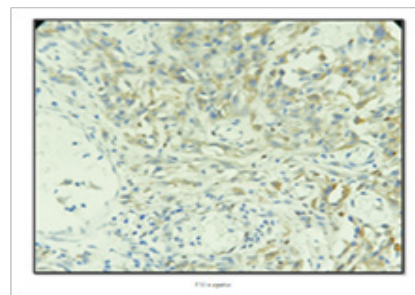


Figure 9: Fli 1 negative

### 5. Discussion and Conclusion

The pathogenesis of angiosarcoma like SCC is not completely understood. Acantholysis, possibly as a consequence of changes in adhesion molecule expression by the tumour cells is suggested to be the underlying pathogenetic mechanism. Despite the presence of E cadherin expression in conventional SCC, loss of E-cadherin expression, leading to the loss of tumour cell-cell adhesion and acantholysis, leads to pseudo lumina formation and further pseudo glandular formation characteristic for this particular type of SCC. Reactive fibrosis in tumor along with acantholysis giving rise to artefactual clefts lined by poorly differentiated malignant cells also may be a reason for angiomatous appearance [5, 6].

Angiosarcoma like SCC has the clinical characteristics of SCC, but histologically may mimic an angiosarcoma. Interestingly in the oral cavity, both these entities show a comparable clinical appearance [7]. The peak incidence of PASCC is in the 6th decade and that of angiosarcoma is in the 7th decade with no sex predilection. Macroscopically, both these entities are fast-growing eruptive lesions in the oral cavity and have a poor prognosis [4].

Histologically, areas of conventional SCC or dysplastic epithelium is mandatory to confirm the diagnosis of this sub variant.4 In addition to the pseudo glandular space, anastomosing of spaces lined by single layer of atypical epithelioid cells, sometimes with luminal RBCs confuses with angiosarcoma.

On immunohistochemistry, pseudovascular variant of SCC shows IHC profile similar to conventional SCC- positivity for P63, laminin, CK, EMA, the only difference being E-cadherin negativity in tumor cell area which is positive in conventional SCC. Angiosarcoma shows an entirely different IHC expression-CD31, CD34, factor 8, FLI-1, CD 131 positivity.

In conventional SCC, Surgery followed by adjuvant based on the

staging is the treatment plan. Surgery is the main stay of treatment in angiosarcoma, a combined modality of treatment, including postoperative radiotherapy, is also recommended [8]. The general outcome of primary angiosarcoma of the oral cavity is good, with a mean survival period of 7.3 to 7.6 years, compared to primary cutaneous and deep soft tissue tumors [8]. Whereas in case of Angiosarcoma like SCC much reports are not available to come to a consensus.

Recognition of PASCC is important because it mimics angiosarcoma and misdiagnosis leads to erroneous treatment. Even though the prognostic significance of this variant is still disputable due to scarcity of published cases, pathologist is asked to take a vigilant call while reporting such cases.

## References

1. Thompson LD. Squamous cell carcinoma variants of the head and neck. *Current Diagnostic Pathology*. 2003; 9(6): 384-96.
2. Cardesa A, Zidar N. Adenoid squamous cell carcinoma. In: Barnes L, Eveson JW, Reichart PA, Sidransky D, eds. *Pathology and genetics of tumours of the head and neck. WHO classification of tumours*. Lyon: IARC. 2005: 129.
3. Zidar N, Gale N, Zuperc A, Dovšak D. Pseudovascular adenoid squamous-cell carcinoma of the oral cavity—a report of two cases. *Journal of clinical pathology*. 2006; 59(11): 1206-8
4. Vidyavathi K, Prasad C, Harendra Kumar ML, Deo RP. Pseudo-vascular adenoid squamous cell carcinoma of oral cavity: A mimicker of angiosarcoma. *J Oral Maxillofac Pathol*. 2012; 16: 288-90.
5. Pitt MA, Morphopoulos G, Bisset DL. Pseudoangiosarcomatous carcinoma of the genitourinary tract. *J Clin Pathol*. 1995; 48: 1059-61.
6. Bayer-Garner IB, Smoller BR. The expression of syndecan-1 is preferentially reduced compared with that of E-cadherin in acantholytic squamous cell carcinoma. *J Cutan Pathol*. 2001; 28: 83-9.
7. Driemel O, Muller-Richter UD, Hakim SG, Bauer R, Berndt A, Klienheinz J, et al. Oral acantholytic squamous cell carcinoma shares clinical and histological features with angiosarcoma. *Head Face Med*. 2008; 4: 17
8. Fomete B, Samaila M, Edaigbini S, Agbara R, Okeke UA. Primary oral soft tissue angiosarcoma of the cheek: a case report and literature review. *Journal of the Korean Association of Oral and Maxillo-facial Surgeons*. 2015; 41(5): 273-7.