

A Rare Case of Amyand's Hernia with Acute Appendicitis

Gligorievski A^{1*}

¹Department of University Clinic of Surgery "St. Naum Ohridski" Skopje, North Macedonia

Volume 4 Issue 4- 2020

Received Date: 03 June 2020

Accepted Date: 16 June 2020

Published Date: 20 June 2020

2. Key words

Amyand's hernia; Inguinal hernia; Appendix; Hernia sac; CT; Appendectomy

1. Abstract

Amyand's hernia is an extremely rare and atypical hernia that is difficult to diagnose clinically characterized by the herniation of the appendix into the inguinal sac. The reported incidence is less than 1% of all adult inguinal hernia cases. Acute appendicitis in Amyand's hernia is even less common, with 0,1% of all cases of acute appendicitis. This hernia may be present without symptoms until the inflammation of the appendix may lead to incarceration, strangulation, necrosis, perforation, or rupture. Early symptoms include tenderness and inguinal swelling.

We report a rare case of Amyand's hernia with acute appendicitis in the inguinal hernia sac that is difficult to diagnose. Amyand's hernia is a rare condition, and difficult to diagnose being commonly found occasionally in diagnostic or surgical procedures. Computer tomography helps make an accurate diagnosis. Computed tomography was the only modality to diagnose the hernia sac contents preoperatively. Today is generally accept that surgical treatment involves hernia repair with or without appendectomy.

3. Introduction

An inguinal hernia is a frequent pathology in surgical practice with an estimated prevalence of 1.2% of the population, with an incidence 12 times greater in the male gender. The contents of the hernia sac may vary from intraperitoneal fat, small or large bowel, bladder, ovaries, and appendix [1]. An Amyand's hernia is a rare type of hernia, characterized by the presence of the appendix, either inflamed or normal, in the inguinal hernia sac. Claudius Amyand was the first who described and treated this condition in 1735 [2]. Amyand's hernia occurs more often in males than females in approximately 1% of all inguinal hernias [3]. The appendix may remain in the hernia sac without symptoms throughout a patient's lifetime. When symptoms do appear, they mimic an incarcerated hernia [4]. The incidence of occurrence of an inflamed or perforated incarcerated appendix in Amyand's hernia is 0.1% of all cases of appendicitis [5]. Amyand's hernia typically presents on the right side. On physical examination, there is tenderness and swelling in the inguinal or inguinoscrotal region [6]. It is clinically difficult to differentiate Amyand's hernia from an inguinal hernia due to their similar presentations. An Amyand's hernia is a diagnostic challenge due to its rarity and diagnosis is often incidental, on imaging or intra-operatively [7-9]. Imaging tests such as Ultrasound (US) and Computed Tomography (CT) aid in distinguishing the pathologies [7, 9, 10]. The US is the initial diagnostic modality of choice in the pediatric population [10]. Computed tomography (CT) allows direct visualization of the appendix inside the inguinal canal and it helps make an accurate diagnosis [7]. Fernando et al. classi-

fied the Amyand's hernia according to the degree of inflammation of the appendix in three types: (A) intact appendix without signs of inflammation; (B) appendix with signs of inflammation; and (C) perforated appendix [11]. Type A accounting for nearly 90% of all cases [1]. Types B and C mandate appendectomy. It is also unclear if there is a causal relationship between the herniation of the appendix and appendicitis. Most investigators believe inflammatory swelling may lead to incarceration and subsequent impaired blood supply and bacterial overgrowth [12, 13].

4. Presentation of Case (Case Report)

This report aims to describe a case of an appendix with signs of inflammation in the inguinal hernia sac, that is rare and difficult to diagnose the condition and highlights the importance of early CT scanning in reaching the exact and early diagnosis of Amyand's hernia.

Herein, we present a rare case of a 69-year-old female patient with a history of intermittent pain in the right inguinal region reported an emergency at the Clinic for Surgical Diseases. On physical examination, she had a right-sided inguinal swelling and tenderness in the right inguinal region. A routine lab test showed an increase in WBC and CRP. After the clinical examination, a diagnosis of right inguinal hernia was made. She was send to the Radiology Department for further evaluation. The patient underwent a CT scan of the abdomen and a small pelvis, and an inflamed appendix was diagnosed. The inflamed appendix is herniated in the inguinal hernia sac. Pathological changes in the parenchymal abdominal and retro-

*Corresponding Author (s): Antonio Gligorievski, University Clinic of Surgery "St. Naum Ohridski" Skopje, E-mail: atglmed@gmail.com

Citation: Gligorievski A, A Rare Case of Amyand's Hernia with Acute Appendicitis. Annals of Clinical and Medical Case Reports. 2020; 4(4): 1-3.

peritoneal organs are not seen. Small bowel loops are free, with no signs of ileus. Free fluid in the abdomen is not seen. After the CT examination of the abdomen and the small pelvis, the diagnosis of Amyand's hernia with acute appendicitis was established (Figure 1-4). The laparotomy was performed in which the inflamed appendix was removed, and the inguinal hernia was resolved. In the end, there was a complete resolution of the case.

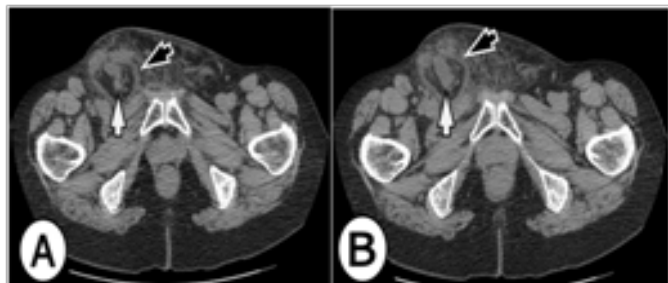


Figure 1: 69-year-old female with right-sided Amyand's hernia. CT scans of the abdomen (A) and (B): Axial CT scan at the level of inguinal regions shows an inflamed appendix (white arrow) extends into the small right inguinal hernia (black arrow). There were no signs of obstruction or strangulation.

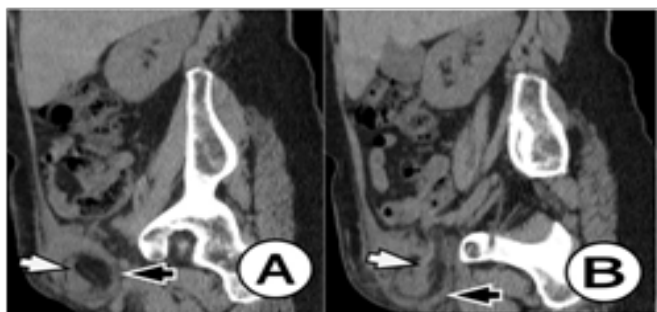

Figure 2: A 69-year-old female with right-sided Amyand's hernia. Sagittal reformatted CT image of the abdomen: Sagittal reformatted CT image shows an inflamed appendix (white arrow) extends into the small right inguinal hernia (black arrow). There were no signs of obstruction or strangulation.

5. Discussion

The contents of a hernia sac are rarely significant in an inguinal hernia, as the sac usually contains small or large bowel or only omentum. However, there can be surprising contents such as Meckel's diverticulum (Littre's hernia), a segment of the bowel's circumference (Richter's hernia), and a portion of the bladder (sliding hernia) or appendix (Amyand's hernia) [1, 3]. Amyand's hernia is a rare type of inguinal hernia where the appendix is located within the hernia sac. This is the case in about 1% of all hernias, and it occurs more frequently in children [14]. Amyand's hernias can be subdivided into two types: direct or indirect inguinal hernias. The appendix may remain perfectly normal but if the diagnosis is delayed, it could become inflamed with subsequent perforation and abscess. However, the incidence of appendicitis within an inguinal hernia is very rare, about 0.1% of all inguinal hernias. Clinical symptoms can be misleading and more often resemble those of a strangulated inguinal hernia than the classic signs and symptoms of appendicitis [15]. Sometimes, a palpable inguinal mass may be present. Only imaging can verify the contents of an incarcerated

inguinal hernia and the approach varies upon those findings. It is generally accepted that surgical treatment includes a hernia repair with or without concomitant appendectomy.

Ultrasound is an excellent technique to evaluate the inguinal region and can be used to detect all types of inguinal hernias, including Amyand's hernia. The US is safe and cheap but remains operator-dependent.

Computed tomography (CT) can be used to confirm the diagnosis if necessary. At the same time, possible intra-abdominal complications like perforation and abscess can be ruled out, especially in a preoperative setting [16]. Complimentary use of ultrasound and contrast-enhanced computed tomography (CT) of the abdomen increases the specificity of detection and diagnostic accuracy to almost 90% [7, 9].

When diagnosis remains unclear, surgery can both be diagnostic and therapeutic. There is no standard protocol for the management of Amyand's hernia. Important determinants for appropriate surgery include the presence of an inflamed appendix, contamination of the surgical field, patient age, and anatomic features [16]. A normal appendix can be returned to the peritoneal cavity or appendectomy can be performed. Treatment depends on the surgeon's personal choice. Removing a healthy appendix is subject to a medical debate, which has not reached a consensus yet [17]. Hernioplasty without appendectomy is a favored option in patients with a normal appendix [12, 18]. In our case report, appendectomy with partial omentectomy followed by mesh repair was performed without any post-operative complications, with broad-spectrum antibiotic cover. In cases of appendicitis, perform appendectomy mast followed by herniorrhaphy [12, 16].

The decision to perform appendectomy and type of hernia repair depends on the intraoperative finding, guided by the Losanoff and Basson's criteria [19]. Appendectomy through the hernia orifice is reserved for Amyand's hernia types 1 and 2, while types 3 and 4 warrants an exploratory laparotomy due to the risk of peritoneal contamination. Mesh repair of the inguinal hernia is generally avoided but may be considered in the absence of appendix inflammation such as in type 1 Amyand's hernia. However, appendectomy is recommended in the younger age group because of higher lifetime risk in developing appendicitis [17].

In this case, the decision to proceed with an appendectomy followed by the mesh-free repair of Amyand's hernia was based on Losanoff and Bosson's criteria for Type 2 Amyand's hernia [19]. The argument for and against the use of mesh during repair of Amyand's hernia remains controversial.

6. Conclusions

Amyand's hernia is rare and difficult to diagnose a condition, being commonly occasionally found in a diagnostic or surgical proce-

dure. It should be remembered in the presence of cases of incarcerated hernias, due to its possible complications if not diagnosed. Ultrasound or CT scan can help in the diagnosis and differentiate an incarcerated reducible inguinal hernia from Amyand's hernia evolving with appendicitis. Appendicitis within an Amyand's hernia is rare, and when it occurs, it is usually misdiagnosed as a strangulated inguinal hernia. This also represents a surgical emergency.

References

1. McIntosh A, Hutchinson A, Roberts A, Withers H. Evidence-based management of groin hernia in primary care, a systematic review. *Family Practice*. 2000; 17(5): 442-7.
2. Amyand C. VII of an inguinal rupture, with a pin in the appendix coeci incrustated with stone; and some observations on wounds in the guts. *Philosophical Transactions of the Royal Society of London*. 1736; 39: 329-42.
3. Michalinos A, Moris D, Vernadakis S. Amyand's hernia: a review. *Am J Surg*. 2014; 207(6): 989-95.
4. Ivashchuk G, Cesmebasi A, Sorenson EP, Blaak C, Tubbs SR, Loukas M. Amyand's hernia: a review. *Med Sci Monit*. 2014; 20: 140-6.
5. Lyss S, Kim A, Bauer J. Perforated appendicitis within an inguinal hernia; a case report and review of literature. *Am Journal of Gastroenterol*. 1997; 92: 700-2.
6. C.D'Alia, Lo Schiavo MG, Tonante A, Taranto A, Gagliano E, Bonanno L, et al. Amyand's hernia: case report and review of the literature. *Hernia*. 2003; 7(2): 89-91.
7. Maizlin ZV, Mason AC, Brown C, Brown JA. "CT findings of normal and inflamed appendix in groin hernia," *Emergency Radiology*. 2007; 14(2): 97-100.
8. Anagnostopoulou S, Dimitroulis D, Troupis TG, Allamani M, Paraschos A, Mazarakis A, et al. Amyand's hernia: a case report. *World Journal of Gastroenterology*. 2003; 12(29): 4761-3.
9. To J, Hanna P, Mohammed R, Trinh S, Vazquez F, Zuberi J, Madlinger R. Amyand's hernia presenting as an unusual inguinal mass: a case report. *Ann Transl Med*. 2017; 5(17): 346.
10. Mebis, M, Hoste, P and Jager, T. Amyand's Hernia. *Journal of the Belgian Society of Radiology*. 2018; 102(1): 1-2.
11. Fernando J, Leelaratna S. Amyand's hernia. *Ceylon Med J*. 2002; 47(2): 71.
12. Sharma H, Gupta A, Shekhawat NS, Memon B. Amyand's hernia; a report of 18 consecutive patients over a 15-year period. *Hernia*. 2007; 11: 31-5.
13. Tsang WK, Lee KL, Tam KF, Lee SF. Acute appendicitis complicating Amyand's hernia: imaging features and literature review. *Hong Kong Med J*. 2014; 20(3): 255-7.
14. Cankorkmaz L, Ozer H, Guney C, Atalar MH, Arslan MS, Koyluoglu G. Amyand's hernia in the children: a single center experience. *Surgery*. 2010; 147(1): 140-3.
15. Ivanschuk G, Cesmebasi A, Sorenson EP, Blaak C, Tubbs SR, Loukas M. Amyand's hernia: a review. *Med Sci Monit*. 2014; 20: 140-6.
16. Logan MT, Nottingham JM. Amyand's hernia: a case report of an incarcerated and perforated appendix within an inguinal hernia and review of the literature. *Am Surg*. 2001. 67(7): p. 628-9.
17. Sadhu J, Samuel VM, Kodiatte T, Gaikwad P. Amyand's Hernia: Case Report -Current Dilemma in Diagnosis and Management. *J Clin Diagn Res*. 2015; 9(2).
18. H Shekhani, Rohatgi S, Hanna T, Johnson JO. Amyand's Hernia: A Case Report. *Radiology Case*. 2016; 10(12): 7-11.
19. Losanoff JE, Basson MD. Amyand hernia: a classification to improve management. *Hernia*. 2008; 12(3): 325-6.