

## A LGI1 Mutation (C.263 T>A P.Leu88\*) Identified in a Chinese Patient with Epilepsy: A Case Study

Zhan W<sup>1</sup>, Zhou E<sup>1</sup>, Mi Y<sup>2</sup>, Zhang J<sup>2</sup>, Zhang Y<sup>2</sup>, Liu H<sup>2</sup>, Dong R<sup>2</sup>, liu X<sup>2</sup>, Han L<sup>2</sup> and Duan J<sup>2\*</sup>

<sup>1</sup>Chengdu Shengkang Epilepsy Hospital, Chengdu 610000, People's Republic of China

<sup>2</sup>Shanxi Guoxin Caregeno Medical Laboratory, Taiyuan 030006, People's Republic of China

### \*Corresponding author:

Jianxiong Duan,  
Shanxi Guoxin Caregeno Medical Laboratory,  
Taiyuan 030006, People's Republic of China,  
E-mail: jianxiong.duan@caregeno.com

Received: 12 Jan 2021

Accepted: 28 Jan 2021

Published: 02 Feb 2021

### Copyright:

©2021 Duan J, et al., This is an open access article distributed under the terms of the Creative Commons Attribution License, which permits unrestricted use, distribution, and build upon your work non-commercially.

### Keywords:

Chinese; Epilepsy; LGI1 gene; Whole exome sequencing (WES); Sanger sequencing; American College of Medical Genetics and Genomics (ACMG)

### Citation:

Duan J. A LGI1 Mutation (C.263 T>A P.Leu88\*) Identified in a Chinese Patient with Epilepsy: A Case Study. *Ann Clin Med Case Rep.* 2021; V5(10): 1-3.

### 1. Abstract

**1.1. Objective:** To investigate the genetic causes of a 13-year-old Chinese female proband with epilepsy.

**1.2. Methods:** Clinical diagnosis and next-generation sequencing.

**1.3. Results:** The proband carries a heterozygous nonsense mutation (c.263 T>A p.Leu88\*) in LGI1 gene. This mutation was evaluated as a pathogenic mutation based on the standards and guidelines of ACMG and clinical research publications.

**1.4. Conclusion:** The heterozygous nonsense mutation (c.263 T>A p.Leu88\*) in LGI1 gene is the genetic cause of epilepsy for the proband. So far, this mutation of LGI1 gene related with epilepsy is the first reported in the worldwide overall populations.

### 2. Introduction

The LGI1 gene is located on the long arm of human chromosome 10 (10q23.33), the protein encoded by this gene can regulate the activities of voltage-gated potassium channels, and is involved in neuron growth regulation and cell survival. The Online Human Mendelian Inheritance Database (OMIM) shows that mutations in the LGI1 gene can cause Familial frontal lobe epilepsy, the disease is usually inherited in an autosomal dominant manner [1]. The syndromes of Familial frontal lobe epilepsy include focal motor seizures, asymmetric rigidity and accompanying excessive movement et al., and it generally occurs during sleep. In this paper, we report the clinical and molecular characteristics of a 13-year-old Chinese female proband with epilepsy. The proband was found to have a heterozygous nonsense mutation in LGI1 gene (c.263 T>A p.Leu88\*), which caused the disease. The mutation was inherited from her affected mother. This mutation of the LGI1 gene has not been

reported in previous studies.

### 3. Materials and Methods

#### 3.1. Clinical Diagnosis

The proband is a 13-year-old female Chinese. She collapsed suddenly on Apr 29, 2020, and has since experienced epileptic seizures. The syndromes last approximately 3 to 5 minutes. She reportedly feels a dizzy before the onset of seizures and is lethargic for about 60 minutes after the seizure. Afterwards, she would completely awake, but still felt fatigued and experienced headaches for a period of time. Her mental state, diet, and sleep all were normal during the intermittent period of the seizure. The following tests were performed for the proband: physical examinations, blood routing, brain MRI, and electroencephalogram.

Family history: According to family statements, the proband's grandmother and mother also had epileptic seizures and their symptoms were the same with the proband. The grandmother died of a brain tumor at the age of 48. The proband's mother, who currently is 42-year-old, had taken phenytoin sodium 0.3 g per day for years. She never had seizures during the medication period. However, if she stopped taking the medication, she would get the seizures. The proband's maternal uncle, 40 years old, had normal ability to work, his intelligence, self-knowledge and social ability are normal. However, he had abnormal behaviors during his adolescence period, such as unconscious running et al., but no syndromes of epileptic seizure were noted. He was diagnosed with mental illness by the local hospital and took 0.4 g sodium valproate and 4 mg Clozapine daily. No abnormalities were noted during the medication period. The proband's maternal aunt, 44 years old, is in good health condition and her son, 22 years old, is also in good health condition.

### 3.2. Molecular Test

In order to study the cause of the disease, whole exome sequencing was performed for the proband and her mother. Furthermore, Sanger sequencing was used to verify the mutation for the proband, her parents, and her relatives (uncle and aunt). Sequencing data was analyzed by using numerous bioinformatics softwares. The pathogenicity of the mutation was evaluated based on the standards and guidelines of ACMG (American College of Medical Genetics and Genomics), Clinvar database, OMIM (Online Mendelian Inheritance in Man), HGMD (Human Gene Mutation Database), and clinical research papers that had been published in scientific journals.

### 4. Results and Analysis

#### 4.1. Clinical Data Analysis

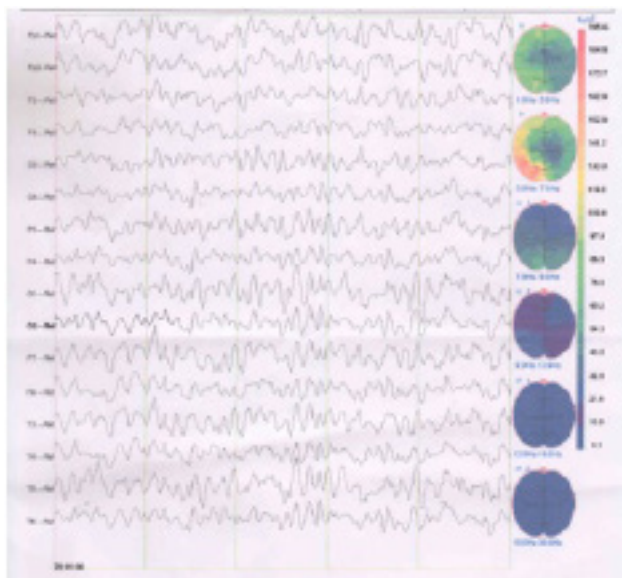
The proband had no abnormalities in her heart, lung, and abdomen. The blood routing, hematuria screening, muscle strength and muscle tension all were normal. Brain MRI showed that no abnormality was found in brain parenchyma. As displayed in (Figure 1), Electroencephalography (EEG) showed abnormal discharge during the awakening and sleeping period.

The proband was diagnosed with Familial frontal lobe epilepsy, and focal seizures developed into generalized tonic-clonic seizures. An antiepileptic drug of Oxcarbazepine 0.3 Bid was prescribed, and the improvement of the syndromes of the proband was observed, as the epileptic seizures did not occur for the proband since Apr. 2020.

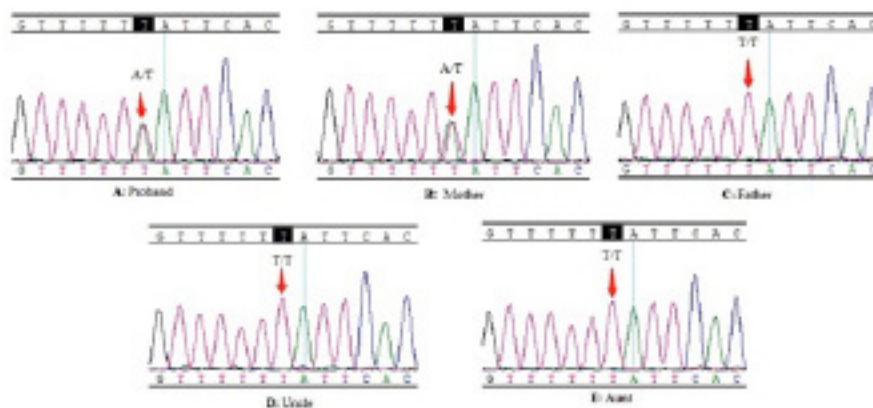
#### 4.2. Molecular Biological Data Analysis

In order to identify the causes of the proband's seizures, we conducted Whole Exome Sequencing (WES) based on Next-generation sequencing for the proband and her affected mother. A heterozygous nonsense mutation in LGI1 gene (c.263 T>A p.Leu88\*) (reference transcript, NM\_001308275) was detected in both of the proband and her mother's DNA. This mutation was further confirmed by Sanger Sequencing, and proved that the mutation is carried by proband and her affected mother, and not detected in her healthy father, her healthy aunt and her uncle. The results indicated that this mutation of the proband was inherited from her mother.

The mutation of c.263 T>A p.Leu88\* in LGI1 gene has not been recorded in any clinical disease-related database (Clinvar and HGMD), nor in



**Figure 1:** The Proband's Electroencephalography (EEG) showed abnormal discharge during awakening and sleeping period.



**Figure 2:** Sanger sequencing of the LGI1 gene mutation (c.263 T>A p.Leu88\*). **A and B:** sequencing results of the proband and her mother showed a heterozygous T-to-A nonsense mutation (red arrows) at codon 263 resulting in amino acid stop gain exchange (p.Leu88\*). **C, D and E:** Wild-type sequence in proband's Father, uncle and aunt (red arrows).

Human genome databases (1000 Genome and Genome mutation frequency database). The function prediction databases (SIFT and polyphen, etc.) all predicted this mutation as harmful. This mutation was evaluated as a pathogenic mutation based on the standards and guidelines of ACMG. So far, this mutation of LGI1 gene related with epilepsy is the first reported in the worldwide overall populations.

## 5. Discussion

Clinvar database provided a review of the molecular genetics of the LGI1 gene, noting that more than 140 different pathogenic mutations had been identified. Most pathogenic mutations are of the single nucleotide (80%) in variation type. The missense substitutions was about 35.8% in the molecular consequence. There were 9 nonsense mutations reported and all of them were evaluated as pathogenic or likely pathogenic and were the causes of the Familial temporal lobe epilepsy 1 disease.

In this case, we evaluated WES data from 350 Chinese patients with epilepsy and identified a 263T>A (p.Leu88\*) nonessense mutation in exon 2 of the LGI1 gene in the proband and her affected mother. The mutation was predicted to generate a premature stop codon, eliminating the last 447 amino acids of the 557 amino-acid protein. The mutation has not been detected in the proband's unaffected maternal uncle and aunt who never had seizures.

The mutation of 263T>A (p.Leu88\*) in the LGI1 gene has not been recorded in the Clinvar database as of today. Our report provided further evidence that the mutation of 263T>A (p.Leu88\*) in the LGI1 is responsible for autosomal dominant partial epilepsy for this family on a genetic level. Based on our study, the interpretation of the clinical significance of this mutation in the Clinvar database may need to be modified accordingly. Our identification of 263T>A (p.Leu88\*) in the LGI1 gene is also provides deeper insights for LGI1 mutations associated with broad clinical spectrum of seizures.

## 6. Conclusion

The identification of nonsense mutation in the LGI1 gene (c.263 T>A p.Leu88\*) in the Chinese patient may further aid in the understanding of the causes of epilepsy. This is a first report of this mutation in the overall population.

## 7. Acknowledgments

We are grateful for the patient and his parents for their generous participation in this study. The authors have stated that they had no interests which might be perceived as conflict or bias.

## References

1. Nobile C, Michelucci R, Andreatza S, Pasini E, Tosatto SCE, Striano P. LGI1 mutations in autosomal dominant and sporadic lateral temporal epilepsy. *Hum. Mutat.* 2009; 30: 530-536.