

Intramural Hematoma of Esophagus After Lifting a Heavy Sack of Rice Which Mimicking Cardiovascular Disorder

Aghajanzadeh M¹, Yousefi-Mashhoor M², Sayhani A³, Foumani AA⁴ and Ildari S^{4*}

¹Department of thoracic surgery, Guilan University of Medical Sciences, Iran

²Department of Gastroenterology, Arya Private Hospital, Iran Guilan University of Medical Sciences, Iran

³Department of cardiology, Arya Private Hospital, Iran Guilan University of Medical Sciences, Iran

⁴Inflammatory Lung Diseases Research Center, Department of Internal Medicine, Razi Hospital, School of Medicine, Guilan University of Medical Sciences, Rasht, Iran

*Corresponding author:

Shima Ildari,
Inflammatory Lung Diseases Research Center,
Department of Internal Medicine, Razi Hospital, School
of Medicine, Guilan University of Medical
Sciences, Rasht, Iran, Tel: 009813-33542460;
Fax: 009813-33542460,
E-mail: sh.ildari1989@gmail.com

Received: 20 Jan 2021

Accepted: 04 Feb 2021

Published: 08 Feb 2021

Copyright:

©2021 Ildari S et al., This is an open access article distributed under the terms of the Creative Commons Attribution License, which permits unrestricted use, distribution, and build upon your work non-commercially.

Citation:

Ildari S. Intramural Hematoma of Esophagus After Lifting a Heavy Sack of Rice Which Mimicking Cardiovascular Disorder.
Ann Clin Med Case Rep. 2021; V5(11): 1-6

Keywords:

Intramural; Hematoma; Esophagus

1. Abstract

1.1. Introduction: We report here a case of an intramural hematoma of the esophagus. The extension of this was from cervical esophagus to lesser curvature of stomach intramural hematoma.

1.2. Case: This very rare event in older women is more common in and can be missed as cardiovascular or emergent disease of esophagus. The most common clinical presentations are severe chest pain, dysphagia or odynophagia and mild hematemesis. The common risk factors are blunt, penetrating or iatrogenic injuries, Valsalva maneuver and antiagulant medication, in literatures spontaneous cases have also been reported.

1.3. Discussion: IEH is a very rare event of esophagus and submucosal esophageal bleeding which can present with acute onset of chest pain, dysphagia or hematemesis and can mimicking some acute cardiopulmonary diseases. These can result in a delayed or even missed diagnosis IHE. Past medical history is very important in such situation. Thus, a high index of suspicion IHE is needed to make the diagnosis and provide the appropriate and best management.

2. Introduction

Intramural hematoma of the esophagus(IHE) is emergency esophageal condition and more common among old people who are taking antiplatelet or anticoagulant drugs [1]. Although the incidence of this event is a rare, Today it is recognized in early stage because of with modern radiological and endoscopic procedure [1-3]. (IHE) divided as spontaneous or secondary and iatrogenic procedural as endoscopy or intraesophageal echocardiography. Secondary causes are traumatic problem. foreign body, severe Valsalva maneuver, lifting heavy weight material, huge bulky bolus

swallowing, severe vomiting, Nasogastric tube, Upper gastric endoscopy or ERCP, nasotracheal intubation and transesophageal echocardiogram [4-8]. Most patients present with at least two of the symptoms in IHE (IHE) usually presents as a sudden and severe onset of a chest or retrosternal pain, and mild hematemesis, and dysphagia or odynophagia. In past medical history of patients There may be a violent retching, vomiting or instrumentation procedure of the esophagus. A history of foreign body swallow rarely may be present [4-7]. In physical examination there are not any specific findings except tachycardia and pallor in the face of patients. It is very important to distinguish IHE from any cause of acute cardiac pain. anticoagulant therapy may worsen the conditions. If the patients present with dysphagia or odynophagia these symptoms can help to exclude significant cardiac reasons from the IHE [6-9]. A PA chest x-ray may show pneumomediastinum, pneumothorax, widening of mediastinum and pleural effusion [1-3,13]. In acute myocardial infarction, dissection of aorta, and thromboembolism of pulmonary artery. In Acute retrosternal chest pain is a common symptom and this disorder should be ruled out with past medical history, carefully physical examination and appropriate diagnostic tools as chest CT-scan, MRI, endoscopy, troponin, CPK EKG and echocardiogram [3-6,13]. The primary and quickly investigation is CT scan with intravenous contrast because CT-scan available in most clinic and centers and is non-invasive tool. Oral contrast study of the esophagus with barium swallow and CT-scan will show multiple filling defect in the lumen of the esophagus. The CT-scan usually show a thickening of esophageal wall with compression lumen of esophagus or obliteration of the lumen by a large hematoma. A contrast CT-scan show

the perforation of esophagus, aorta, mediastinal structures and also mediastinitis. Oral contrast imaging indicated when transmural perforation of esophagus suspected [1,2,14-16]. MRI is useful tools for diagnosing of (IHE) [16]. The use of Endoscopy indicated the integrity of the esophagus wall had been intact and not be perforated and can be performed with care. An esophacoscopy usually show a blue color swelling or edema with or without a mucosal tear or lacerations. Endoscopic ultrasound is superior to plain endoscopy. When pneumothorax, pneumomediastinum, or pleural effusion presence imaging strongly show a transmural injury to with the intramural hematoma of esophagus [5]. EKG, Chest x-ray and cardiac Lab date should be perform to exclude other cardiopulmonary and vascular diseases [1-4] Treatment of IHE is usually conservative. The initial management is stop oral intake. Intravenous IV therapy, coagulopathy should be correct, and intravenous of proton pump inhibitors should be administration [3-6]. A serial oral contrast CT scan or barium swallow study is needed for monitoring of clinical progress and condition or resolution of hematoma. The patient is gradually administration oral feeding with water when symptoms resolution. Conservative treatment respond and full recovery in most patients. Hematoma may leakage in the pleural space or rupture into the esophageal lumen in rare cases. When hematoma expand, the patient should be managed with protection the airway and hemodynamic and cardiovascular resuscitation. Transarterial angiography and embolization may become necessary for stopping bleeding and hematoma preventions. Surgery usually is indicated for patient who bleeding and hematoma do not respond to conservative therapy and associated with poor outcome [17-19]. IHE is a benign condition but are very grave. Conservative treatment respond in Most patients with fully recover. Prognosis is very good and IHE resolves in 3-4 weeks[15-18]. herein we want to show our experiences in management of IHE.

3. Case Presentation

A 65-year-old male man referred to our hospital with sever retrosternal, chest pain dysphagia, and mild hematemesis. Six hour prior to admission, he was lifting a big sack full of rice and developed acute onset dysphagia with retrosternal pain difficulty swallowing food epigastrium tenderness and increase saliva mix with blood. Four hour later, he developed sudden onset sharp retrosternal chest pain associated with mild bright red blood hematemesis in our hospital. Before lifting the sack of rice He denied having any problem as odynophagia, abdominal pain, nausea, vomiting or fever. In emergency room, his blood pressure was 14/82 mmHg and pulse rate 100 p/m. On Physical examination of head and neck, chest and abdomen was normal. Laboratory finding showed hemoglobin 12 g/dl, hematocrit 36%, platelets 350,000/uL coagulation profile. Was normal. (BUN) was 21 mg/dL with serum creatinine 0.9 mg/dL. Electrocardiogram (EKG), CPK-mb and troponin was in normal range. CT -scan of chest with oral and intravenous contrast showed esophageal narrowing at the upper ,middle and distal part of esophgouse lumen and also show mural thickening and a soft tissue density in the esophagouse which extending to the lesser girvature of stomach due to esophageal hematoma (Figure 1,2,3,4). CT-scan of abdomen with oral and IV contrast showed circumscribed hyperdense structure in the distal esophagus concerning for an intramural esophageal hematoma and extending inferiorly to the proximal portion of stomach (Figure 5,6). He was withdrawal few days nothing by mouth at first and few days started on IV fluids and pantoprazole, cef-

triaxone and clindamycin infusion. With this conservative management, his and in this time his diet was advanced to clear liquid Four days after improved of symptoms, he underwent barium swallow. We performed an oral contrast imaging for transmural perforation or Extravasation of oral contrast extraluminally. intravenous and oral contrast showed esophageal luminal narrowing at the distal third with mural thickening and a soft tissue density extending to the gastroesophageal junction due to esophageal hematoma (Figure 7) and an esophagogastroduodenoscopy which showed a blue like discoloration at the distal third of the esophagus and a non-bleeding ulcer at the distal esophagus and proximal stomach and narrowing the luman of esophagouse due to hematoma (Figure 8, 9,10,). biopsies were not because of recent bleeding and hematoma. He was started on a normal and soft diet with oral pantoprazole 40 mg twice daily, he tolerated well and was discharged home. He did not have any compliant or recurrence of his symptoms.

4. Discussion

Intramural hematoma of the esophagus as intramural rupture or intra wall bleeding of esophagus whiteout perforation is a rare condition which collection of blood in the esophagus wall of (1,2,3) A review of literatures which shows the average age of patients is 58.8 years and some peak of age are greater or around the 70 years. IHE is slightly more frequent in female's patients [1]. Our case age was 65 years old and was male. The causes Intramural hematoma of the esophagus are abnormal hemostasis, vomiting, trauma, iatrogenic trauma, Coagulation disorders, anticoagulant or Antiplatelet drugs and hemostasis disorders [1-3]. Antiplatelet drug is not the cause of IHE but can aggravating factors and can increase extentation of the hematoma [1,4,7,8,14]. Valsalva maneuver Vomiting, sever coughing, sever sneezing, swallowing big compact or bulky bolus foods, or lifting a heavy weight material are others cause of IHE. [1,7,8] The mechanism of IHE is a sudden change and increase in intrathoracic and esophageal pressure during swallowing or vomiting [1,3,7,9]. In our case, lifting a heavy weight sack of rice was the cause of the precipitating factor and the located of IHE was in the upper, middle and lower third portion of the esophagus and EGJ [1-4]. Distal of esophagus In (83%) of cases is commonly the site of injury in IHE. The reason is the absence of striated muscle in this portion and this region is support by some organ such as trachea and heart and by the fiber of the muscularis in the gastroesophageal junction of stomach [1,4,5,7] The middle third of the esophagus is involved in 78% and the proximal third involve in 27% [1]. The mucosal tearing are usually transverse and submucosal hematoma can rupture in the esophageal lumen (1.5). In our case the upper, middle and lower third of thoracic esophagus and proximal portion of stomach was involved. Other causes of IHE are direct injuries are endoscopic procedure interventions, ingested food and other matter or external injury of the chest wall [1,3,7,19]. Case reports show IHE can present after varix sclerotherapy, esophageal ballon dilatation, pill and forigen body impaction or traffic truma and accidents [1,4,9] Aortoesophageal fistula is a rare life-threatening cause of IHE [6,9,10]. Secondary causes of IHE are foreign body ingestion, esophageal malignancies, corrosive esophagitis and penetrating ulcer due to truma [1,4,7,8] In 19% of cases, the cause IHE are unkwon and no risk factor is described. Esophageal motility disorder can produce an intramural hematoma [1]. The clinical presentation of patients are chest pain in (84%) of patients, dysphagia or odynophagia in (59%),

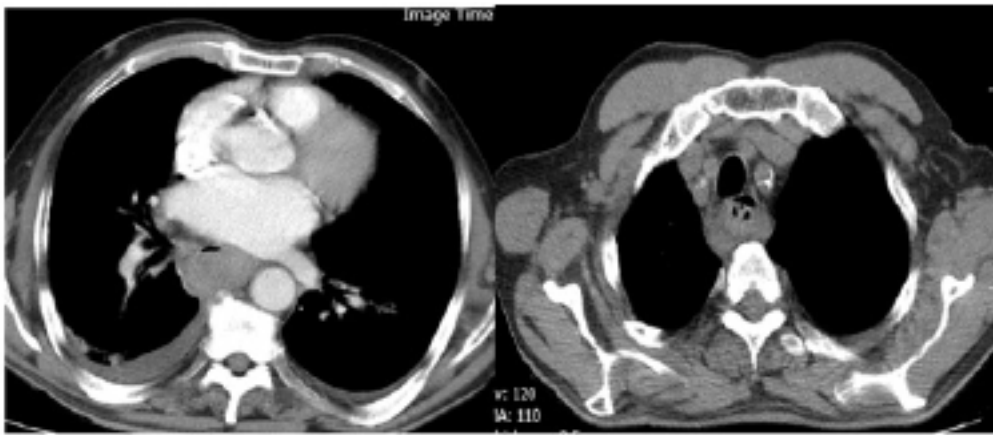

Figure 1 and 2: CT-scan of the chest show (IHE) upper portion of esophageal and leakage of blood to pleural space.

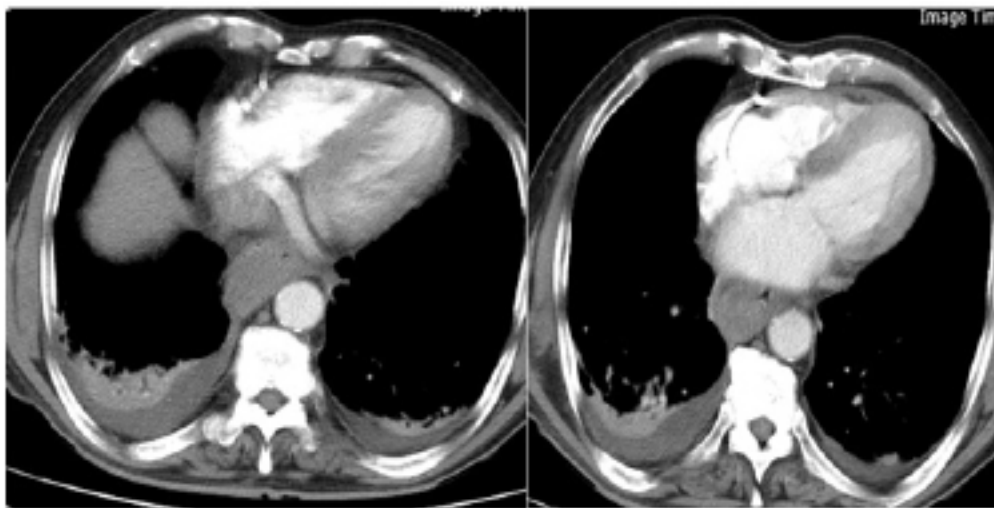


Figure 3 and 4: CT-scan of the chest show (IHE) middle portion of esophageal and leakage of blood to pleural space.

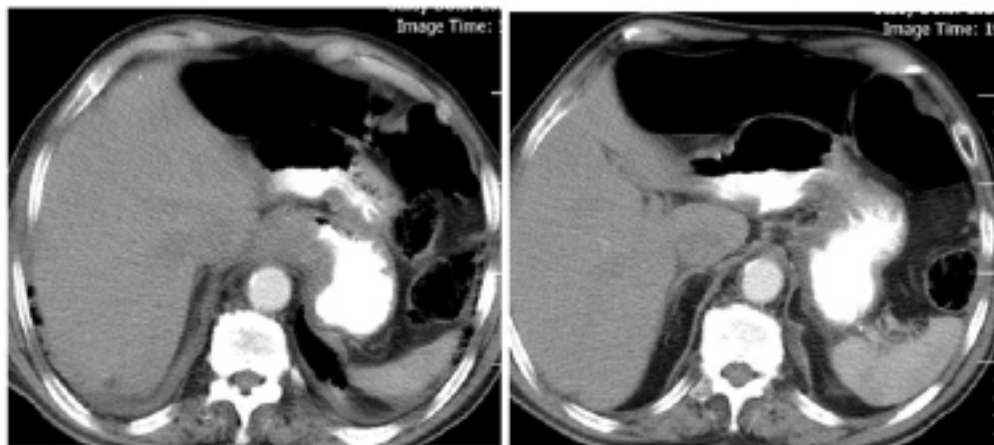


Figure 5 and 6: CT-scan of the chest show (IHE) lower portion of esophageal and EGJ with hematoma.

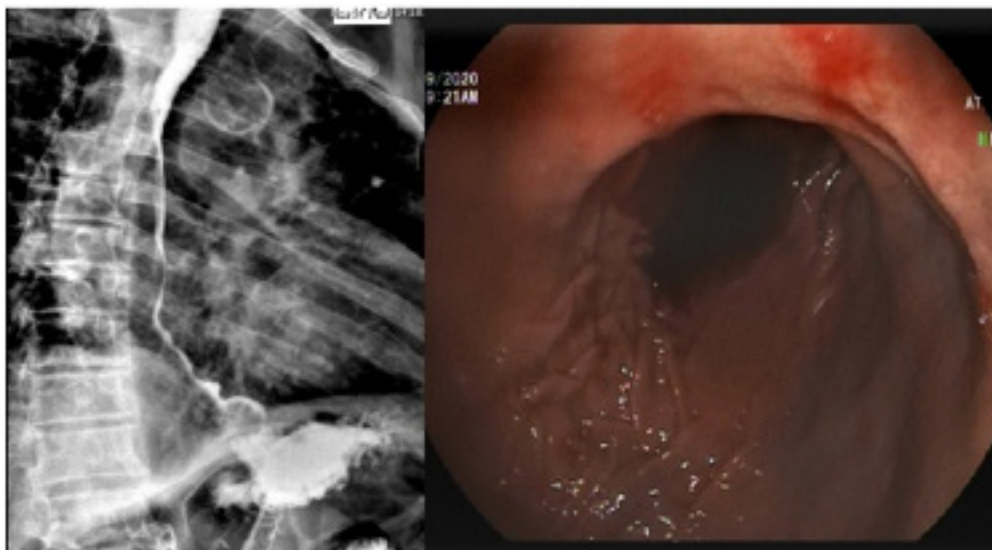

Figure 7 and 8: Oral contrast swallow showed esophageal luminal narrowing at upper, middle, lower and EGJ of esophagus with mural thickening of esophagus and a soft tissue density extending to lesser curvature of stomach concerning for esophageal hematoma without perforation.

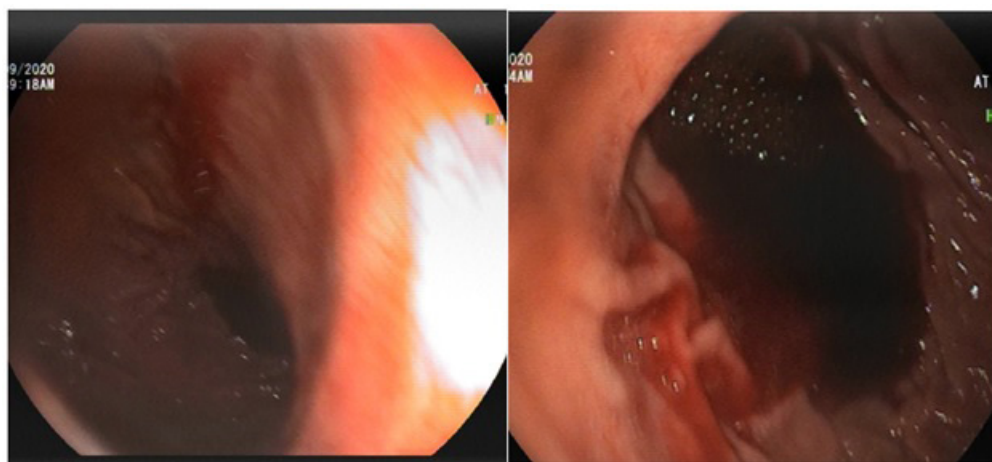


Figure 9 and 10: Esophagogastroduodenoscopy which showed a blue color at the distal third of the esophagus and a non-bleeding ulcer at the distal esophagus and proximal stomach and narrowing the lumen of esophagus.

with minor hematemesis in (56%) of patients. Ninety percent of patients have only one of these symptoms, seventy nine present have two or more of symptoms and one third have all of symptoms [1-4,6]. The chest pain is usually is sudden, severe and retrosternal as Our patient had severe chest pain, dysphagia, odynophagia and mild hematemesis, epigastric pain occasional radiating to the back [1,2]. The hematemesis occurs after rupture of the hematoma through the esophageal mucosa [3,4]. Clinical finding in some patients show low blood pressure, tenderness of epigastrium or low-grade fever [1,3]. But in our case we did not find any clinical sign as fever and low blood pressure. The differential diagnosis of IHE includes esophageal disease as Boerhaave, Mallory-Weiss syndrome (MWS) and motility disorder [6,9]. A complete transmural rupture of the esophagus in distal portion due to sudden increase of intraesophageal pressure, during severe vomiting or cough, blunt trauma, child birth, straining and weight lifting, intraesophageal pressure increase [6,9]. In MVS after vomiting, the patient present with lower thoracic chest pain and subcutaneous emphysema usually in the neck. A longitudinal mucosal tear at the gastro-

esophageal junction occur in MVS following severe cough, retching or forceful vomiting MVS occur and The usual symptom is hematemesis [6]. The prognosis is good with supportive care and treatment [6,9]. IHE can also be misdiagnosed with peptic ulcer perforated and acute pancreatitis [6]. Other differential diagnosis are ischemic heart disease, dissection, rupture or dissection of thoracic aorta or pulmonary embolism and pneumothorax (1,3,9,10) Electrocardiogram, chest X-ray and laboratory tests as CPKmb, troponin, d-dimer and amylase and lipase can help for diagnosis of cardiovascular, respiratory disorder and pancreas [7]. For diagnosis of IHE medical historically, barium or Gastrografin swallow study of esophagus [1,3,9,10]. But today, CT-scan of chest or MRI of chest and upper gastrointestinal endoscopy are used [2,9,11]. Endoscopic ultrasonography is sometime performed and recommended [1,2,9]. Historically, for evaluation of IHE, Barium or Gastrografin swallow was the first choice of radiological imaging [16]. This imaging showing an long segment of tubular filling defect with smooth border or showing the dissection space or the lumen filling with contrast in the esophagus [1,2,3,16]. To days CT-

scan of chest is the first rapid and noninvasive radiological investigation of choice and can rule out other thoracic pathologies [1,4,16]. CT-scan of chest usually shows symmetric or asymmetric esophageal wall thickening of the esophageal wall [2,4]. The other imaging for investigation is MRI. MRI shows a mass of intermediate signal intensity on T1- and T2-weighted image and also shows the extension of the hematoma in several planes and can differentiate esophageal lesions from mediastinal masses or pathologies [15,16]. Esophagogastroscopy usually shows a large blue or purplish lesion in the posterior portion of esophagus [4,5,9,13] or sometimes show mucosal erosions, ulcerations or necrosis [5,9,10,11]. Endoscopic ultrasonography can be helpful to show underlying intramural or luminal esophageal tumors or vascular lesions [9,11,13]. In our case, after roll-out of the cardiovascular problem, we performed a CT-scan of the chest and esophagoscopy with care that showed the same lesions as described in our case presentation. Treatment is conservative with no oral food or drink intake, with intravenous fluid and correction of any coagulopathy, then a progressive give the patients fluid and soft diet [1,2,4]. Antibiotics are not used routinely, except for rare cases of infection in the submucosal layer [1,4]. Surgery is contraindicated in IHE except for esophageal perforation in the pleural or mediastinum space, uncontrolled hemorrhage or complicated abscess [6,10,12]. If spontaneous resolution does not happen, endoscopic incision of the mucosal layer has been described [6,10,12]. Prognosis is very good and resolution happens about 2 to 3 weeks full recovery happens in (75%). [15-18] like in our case. Mortality has been reported after thoracotomy or in very ill white cardio-pulmonary patients [1,4]. Recurrent massive bleeding was reported in some case reports and this bleeding managed with arterial embolization [19]. In achalasia recurrence of bleeding was reported [1,19]. The IHE can be followed by endoscopy or Endoscopic ultrasonography [9,10,13].

5. Conclusions

In conclusion, IEH is a very rare event of esophagus and submucosal esophageal bleeding which can present with acute onset of chest pain, dysphagia or hematemesis and can mimic some acute cardiopulmonary diseases. These can result in a delayed or even missed diagnosis IHE. Past medical history is very important in such situation. Thus, a high index of suspicion IHE is needed to make the diagnosis and provide the appropriate and best management.

Reference:

1. Strowd RE, Agborbesong P, Eapen M, Ervin S. Intramural hematoma of the esophagus presenting as chest pain. *J Hosp Med*. 2010; 5: 421-423.
2. Mandavdhare HS, Gupta P, Maity P, Sharma V. Image Diagnosis: Esophageal Intramural Hematoma in Sudden-Onset Chest Pain and Dysphagia. *Perm J*. 2018; 23: 18-14112.
3. Cullen SN, McIntyre AS. Dissecting intramural haematoma of the esophagus. *Eur J Gastroenterol Hepatol*. 2000; 12: 1151-1162.
4. Wang AY, Riordan RD, Yang N, Hiew CY. Intramural haematoma of the oesophagus presenting as an unusual complication of endotracheal intubation. *Australas Radiol*. 2007; 51 Suppl: B260-4.
5. Randhawa MS, Rai MP, Dhar G, Bandi A. Large oesophageal haematoma as a result of transoesophageal echocardiogram (TEE). *BMJ Case Rep*. 2017; 2017
6. Mata Caballero R, Oteo Domínguez JF, Mingo Santos S, Garcia Touchard A, Goicolea Ruigómez J. Large dissecting intramural haematoma of the oesophagus and stomach and major gastro-oesophageal bleeding after transoesophageal echocardiography during transcatheter aortic valve replacement procedures. *Eur Heart J Cardiovasc Imaging* 2018; 19(8): 955.
7. Yamada T, Motomura Y, Hiraoka E, Miyagaki A, Sato J. Nasogastric Tubes Can Cause Intramural Hematoma of the Esophagus. *Am J Case Rep*. 2019; 20: 224-227.
8. Zippi M, Hong W, Traversa G. Intramural hematoma of the esophagus: An unusual complication of endoscopic retrograde cholangiopancreatography. *Turk J Gastroenterol*. 2016; 27(6): 560-56.
9. Ouatu-Lascar R, Bharadhwaj G, Triadafilopoulos G. Endoscopic appearance of esophageal hematomas. *World J Gastroenterol*. 2000; 6: 307-309.
10. Wong YM, Makmur A, Lau LC, Ting E. Temporal Evolution of Intramural Esophageal Dissection with 3D Reconstruction and Cinematic Virtual Fly-Through. *J Radiol Case Rep*. 2018; 12(2): 11-17.
11. Hagel J, Bicknell SG, Haniak W. Imaging management of spontaneous giant esophageal intramural hematoma. *Can J Assoc Radiol*. 2007; 58: 76-78.
12. Cao DT, Reny JL, Lanthier N, Frossard JL. Intramural hematoma of the esophagus. *Case Rep Gastroenterol*. 2012; 6(2): 510-7.
13. Hsu CC, Changchien CS. Endoscopic and radiological features of intramural esophageal dissection. *Endoscopy*. 2001; 33: 379-381.
14. Trip J, Hamer P, Flint R. Intramural oesophageal haematoma-a rare complication of dabigatran. *New Zealand Med J*. 2017; 130(1456): 80-82.
15. Kamphuis AG, Baur CH, Freling NJ. Intramural hematoma of the esophagus: appearance on magnetic resonance imaging. *Magn Reson Imaging*. 1995; 13(7): 1037-42.
16. Choi HK, Law S, Chu KM, Wong J. The value of neck drain in esophageal surgery: a randomized trial. *Dis. Esophagus*. 2017; 11(1): 40-42.
17. Vossler JD, Abdul-Ghani A. Esophageal Hematoma following Acute Esophageal Barotrauma. *Am Surg*. 2017; 83(6): e213-215.
18. Trip J, Hamer P, Flint R. Intramural oesophageal haematoma-a rare complication of dabigatran. *New Zealand Med J*. 2017; 130(1456): 80-82.
19. Shim J, Jang Y, Hwangbo Y, Dong SH, Oh JH, Kim BH, et al. Recurrent massive bleeding due to dissecting intramural hematoma of the esophagus: treatment with therapeutic angiography. *World J Gastroenterol*. 2009; 15: 5232-5235.