

Yolk Sac Tumor as a Rare Cause of Esophageal Stricture in a 5-Year-Old Girl: A Case Report and Review of Literature

Velmishi V^{1*}, Marku F¹, Qordja M², Saraci B³, Bali D⁴, Heta S⁵ and Cullufi P¹

¹Service of pediatric nr 2 “Mother Teresa” Hospital-Tirana, Albania

²Histopathology service at “At Luigji Monti” Clinic, Tirana, Albania

³Service of pediatric radiology “Mother Teresa” Hospital-Tirana, Albania

⁴Service of pediatric hematology “Mother Teresa” Hospital-Tirana, Albania

⁵Service of pediatric surgery “Mother Teresa” Hospital-Tirana, Albania

*Corresponding author:

Virtut Velmishi,
Service of pediatric nr 2 “Mother Teresa”
Hospital-Tirana, Albania,
E-mail: tutimodh@yahoo.com

Received: 25 Feb 2021

Accepted: 19 Mar 2021

Published: 25 Mar 2021

Copyright:

©2021 Velmishi V et al., This is an open access article distributed under the terms of the Creative Commons Attribution License, which permits unrestricted use, distribution, and build upon your work non-commercially.

Citation:

Velmishi V. Yolk Sac Tumor as a Rare Cause of Esophageal Stricture in a 5-Year-Old Girl: A Case Report and Review of Literature. Ann Clin Med Case Rep. 2021; V6(7): 1-5.

Keywords:

Yolk sac tumor; Esophageal stricture

1. Abstract

Yolk Sac Tumor (YST), which most frequently arises in the gonads as a type of germ cell tumor, is rare in children but is highly malignant. There are a number of diagnostic tools applied for YST, such as US, CT, Magnetic Resonance Imaging (MRI) and histopathological analysis.

We report a rare YST case in a 5-year old girl, in terms of the clinical manifestation, imaging, endoscopy, histopathology findings and diagnosis. It is important to investigate more thoroughly a child with history of frequent vomiting mimicking esophageal stricture because this might be the critical sign of neoplastic invasion to the esophageal wall, that should be alarmed for early treatment. Although YST is rare in children, pediatric physicians should be aware of this and prompt treatment should be addressed.

2. Introduction

Pediatric Germ Cell Tumors (GCTs) are rare tumors of childhood and make up only 3.5% of all childhood cancers for children under the age of 15 years. The incidence increases around 15-19 years of age, and goes to 16%. Approximately one-third are extragonadal neoplasms and the most common sites are the sacrococcygeal or retroperitoneal region, and the pineal gland. The incidence of extragonadal tumors varies widely by age (higher in younger age

and gender (more often in girls at a younger age, while intracranial/intraspinal tumors are more common in boys at an older age [1-4]. The only known risk factor, based on studies and literature review, for extragonadal GCTs is the presence of Klinefelter syndrome (47, XXY karyotype). In that case, there is an increased risk of developing mediastinal GCTs in early adolescence [5].

GCTs are a heterogeneous group of malignant tumors with a variety of histopathological features. Yolk sac tumor is the predominant variant in newborns and younger children. Most common findings in histological examination is microcystic (reticular) pattern and are cytokeratine positive. Alpha Fetoprotein (α FP) elevation is associated with yolk sac tumor and can be used for diagnosis. Diagnostic tools applied for YST include, US, CT, Magnetic Resonance Imaging (MRI) and histopathological analysis.

In this study we reported a rare YST case in a 5-year old girl, in terms of the clinical manifestation, imaging, histopathology findings and diagnosis.

3. Case Presentation

A patient, a 5 year-old girl, was referred to our institution (pediatric gastroenterology service) for evaluation. She had one month, presenting the following symptoms: vomiting after eating, weight loss, and loss of appetite. She had visited several times local clin-

ics and regional hospitals as well. To the patient was prescribed oral omeprazole, but her symptoms persisted. During one month, episodes of vomiting come to be more frequent and she lost more than 1 kg. In the regional hospital, she was submitted to various examinations without a precise diagnosis.

She was the fourth child of the couple. Pregnancy and delivery were normal. Birth weight was 2800 gr. She has been vaccinated according to Albanian schedule. The parents reported that her appearance was normal during the first five years of her life. Subsequently, they noticed that she appeared to be thinner and fatigued. On the physical examination, the patient was pale. The patient weight was 16kg (-1.6 SD), while the height was 110 cm (-0.9 SD). Respiratory rate and heart rate were normal. Breath sound was clear. Abdomen was soft: the patient had no enlarged liver or spleen.

Laboratory results were as follows:

WBC=13.9x 10³/mm³, RBC=4.5x 10⁶/mm³, HGB = 9.5g/dl, PLT=459x 10³/mm³

Anti- transglutaminase antibody was normal; Ferritinemia=102.3ng/ml, PCR=3.74mg/dl

(normal range < 0.5), fibrinogen =533mg/dl (normal range 130-360), LDH= 646 U/L,

Abdominal ultrasound was normal.

Upper gastrointestinal series- barium swallow examination

showed an obstruction of lower third of esophagus, which suggested food bolus.

After that, the patient underwent an upper digestive endoscopy. The endoscopy findings showed remnant food and an adherent mass in the esophageal lumen (Figure 2, on the left). It was impossible to visualize the lower esophageal sphincter. The endoscope could not pass to the stomach. Endoscopy findings

suggested esophageal stenosis. CT- scan of the thorax and abdomen showed a solid mass located in the posterior-inferior mediastinum with direct invasion to the left inferior bronchus and thoracic aorta. Lower part of esophagus was deviated antero-laterally. CT- findings suggested a tumor- like solid mass located in the posterior- inferior mediastinum (Figure 2 on the right). During the hospitalization period, child lost 2 kg, since the episodes of vomiting became even more frequent. She could not tolerate having anything, even liquids passing through from her mouth.

Neuron specific enolase was required (we suspected about a neuroblastoma tumor), examination of which resulted negative. Total urine catecholamines=108mcg/24h. AFP was more than 20000 ng/mL. The patient underwent a laparotomy procedure to take biopsy (Figure 3). Exploratory laparotomy showed a solid mass located from abdominal region to posterior mediastinum, near to esophagus. A gastrostomy feeding tube (PEG tube) was inserted to the patient.

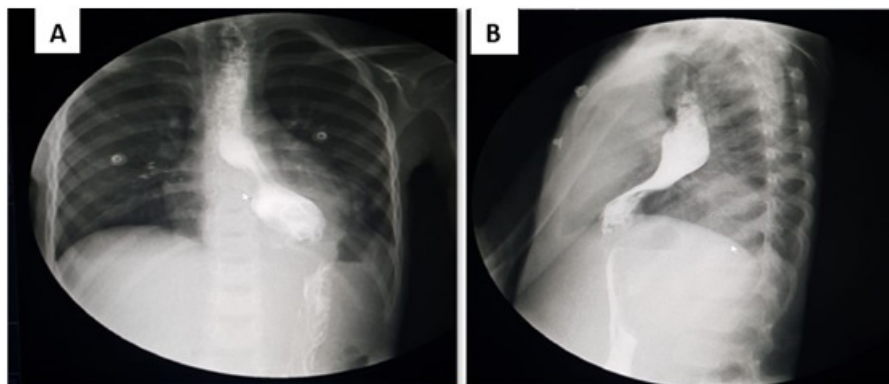


Figure 1: The barium swallow in the anteroposterior (A) and lateral views (B)

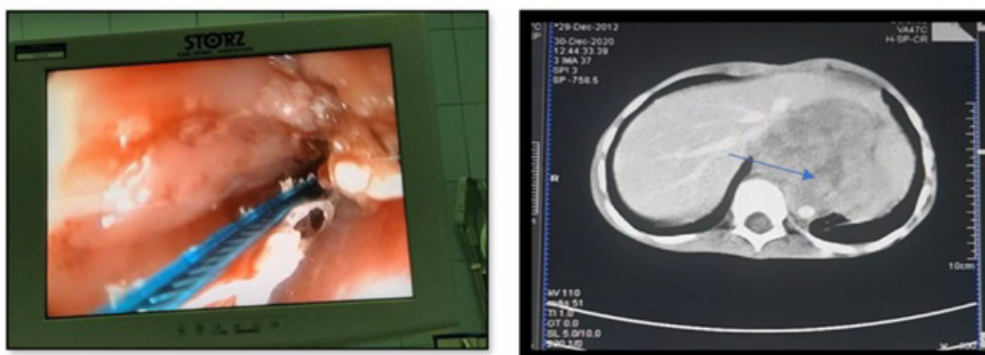


Figure 2: Endoscopic view of distal esophageal shows adherent mass and severe stenosis (on the left) and CT revealing a large mass between abdomen and mediastinum (on the right)

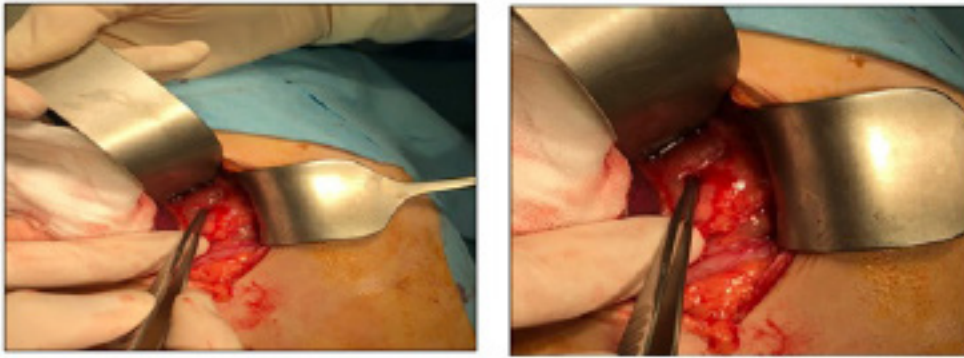


Figure 3: Intraoperative view during exploratory laparotomy

She started being fed from the PEG tube. During this period, the patient was treated with antibiotic therapy (prophylactic dosage after laparotomy), omeprazole, fluid replacement and albumin infusion.

Histological examination showed: atypical tumor cells which form cords of cells, microcystic structure which is characterized by the presence of a spider web network formed by vacuolated cytoplasm of tumor cells, similar to a honeycomb. Microcysts con-

tain eosinophilic material.

Histological and immunohistochemistry examinations found malignant neoplasm, yolk sac tumor. Based on the histological and immunohistochemistry examinations findings, the patient was diagnosed with yolk sac tumor located from abdominal region to posterior mediastinum, near to esophagus. The patient refers to the oncology department for specific treatment.

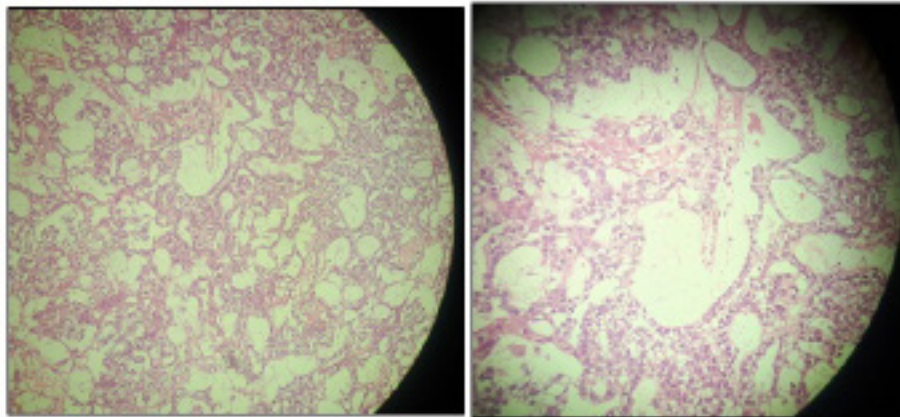


Figure 4: microscopic (histologic) images

Immunohistochemistry examination resulted cytokeratin positive and S-100 negative.

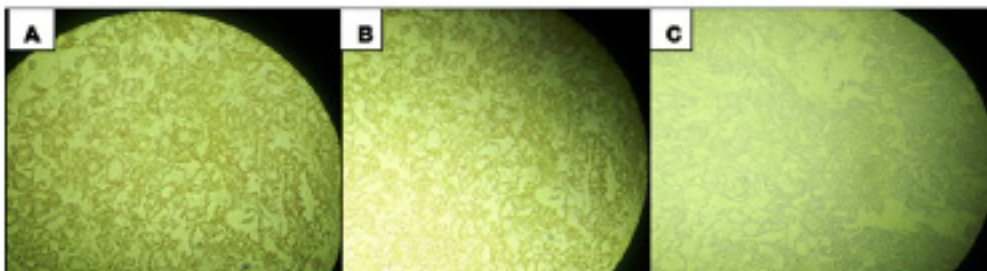


Figure 5: immunohistochemistry images: A&B cytokeratin AE1/3 positive. C- S-100 negative

4. Discussion

YST is a rare tumor of childhood and usually arises in gonads, testis or ovary, thus a type of germ cell tumor. Approximately one-third are extra-gonadal origins, such as vagina, cervix, endometrium, mediastinum, pineal gland, and sacrococcygeal area. It

has also been reported that YST occurred in penile shaft, urachus, stomach, liver, lungs, heart, thyroid, nasal region, cranial base, mesentery, mouth, ears, omentum, eyes, vulva, retroperitoneum, prostate, pericardium, diaphragm, and subcutaneous region [1-4]. Malignant Ovarian Germ Cell Tumors (MOGCTs) are classified in two types, germinomatous and non-germinomatous. YST are the

commonest non-germinomatous MOGCTs. About 85% of YST in children, presented as clinical stage I in comparison with 35% in adults. [6, 7].

There are a number of diagnostic tools applied for YST, such as US, CT, Magnetic Resonance Imaging (MRI) and histopathological analysis. US characterizes the adnexal mass. CT scan permits detection of carcinosis and adenopathy even though lymph node involvement is rare in this type of germinal malignancy, MRI reveals the hyper-vascularized and hemorrhagic feature of the mass [8]. Based on mass location, exploratory laparotomy is emerging as a tool to detect the details of the tumor and surrounding involvement and also for biopsy [2, 11].

There are number of histopathological subtypes of YST. In newborns and younger children, YST are predominant variant, whereas there are a wide variety of subtypes in adolescent. The typical histological aspect is a clear cell proliferation organized in network generally of micro-cystic aspect. Schiller-Duval bodies are cellular structures that resemble fetal glomerulus, pathognomonic of endodermal tissue, frequent mitotic figures and are cytokeratin positive [9,10].

Alpha Feto Protein (α FP) elevation is associated with yolk sac tumor. Also, response to chemotherapy could be assessed by the AFP level. However, the studies suggest a slight increase in AFP should not be applied as the sole criterion for chemotherapy decision [6, 11, 12].

The exact pathogenesis of YST remains obscure. However, some studies propose that it occurs from malignant transformation of misplaced germ cells [13].

The general treatment for YST is surgery for eliminating the primary tumor without severe morbidity. Previous studies in patients with stage I YST, proved that treatment of adnexectomy showed equivalent results to extensive surgery. The treatment of OGCTs in the advanced stage generally involves debulking surgery of tumors followed by adjuvant chemotherapy [16]. Most studies support the regimen of BEP (bleomycin, etoposide, and cisplatin) for primary treatment of the OGCT patients [8]. Chemotherapy may improve the prognosis between 20–50% for YSTs [14]. The combination of cisplatin, bleomycin and etoposide has been demonstrated to be effective, and is the most common type of chemotherapeutic regimen [15].

All cases of YST should receive adjuvant chemotherapy except primary testicular tumors, which exhibit excellent responses to surgery alone [17].

Our case highlights the importance of knowing YST in children. Initially we thought more for an esophageal stricture because ultrasound erroneously has not revealed the mass describing it as a large stomach. After barium swallow, it was suspected food impaction because of enlargement of lower part of esophagus. During

upper endoscopy we found some foods above the stricture. We removed them endoscopically and tried to go into stomach but esophageal lumen was obstructed. Esophageal wall was infiltrated by unknown mass. We performed a CT with contrast which revealed exactly the tumor. Briefly we summarized our diagnostic procedures because a tumor is not frequent as a cause of esophageal stricture. The most common causes are strictures caused by gastroesophageal reflux or eosinophilic esophagitis. Some other causes are caustic injury or esophageal stricture after surgery. Some esophageal stricture are present at birth called congenital esophageal strictures. After upper endoscopy it was important to investigate more thoroughly a patient with history of frequent vomiting shortly after a meal, because this might be the critical sign of invasion of the esophageal wall by a tumor. Although YST is rare in children, pediatric physicians should be aware of this and prompt treatment should be addressed.

5. Conclusion

Children presented with signs of esophageal stricture should be evaluated thoroughly because tumors that infiltrate esophageal walls may be a serious cause. Also it is important that clinicians are aware that yolk sac tumor can present in an unusual extragonadal place.

References

- Bernstein L, Smith M, Liu L, Ries L, Melbert D, Krapcho M. Germ cell trophoblastic and other gonadal neoplasms ICCC X 1975–2004. SEER Cancer Statistics Review. Bethesda: National Cancer Institute; 2007;125-37.
- Watanabe N, Okita H, Matsuoka K, Kiyotani C, Fujii E, Kumagai M, et al. Vaginal yolk sac (endodermal sinus) tumors in infancy presenting persistent vaginal bleeding. *J Obstet Gynaecol Res.* 2010; 36: 213-6.
- Sudour-Bonnange H, Orbach D, Kalfa N, Fasola S, Patte C. Germ cell tumors in atypical locations: experience of the TGM 95 SFCE trial. *J Pediatr Hematol Oncol.* 2014; 36: 646-8.
- Lightfoot MA, Bilgutay AN, Kirsch AJ. A rare case of pediatric vaginal yolk sac tumor. *Urology.* 2018; 119: 137-9.
- Hasle H, Jacobsen BB. Origin of male mediastinal germ-cell tumours. *Lancet.* 1995; 345: 1046.
- Guida M, Pignata S, Palumbo AR, Miele G, Marra ML, Visconti F, et al. Laparoscopic treatment of a Yolk Sac Tumor: case report and literature review. *Transl Med Uni Sa.* 2013; 7: 1-5.
- Christopher SC. Prepubertal Testicular and Paratesticular Tumors: Medscape Reference. New York, NY: WebMD LLC. 2011.
- Eddaoualline H, Sami H, Rais H, Belbaraka R, El Omrani A, Khouchani M. Ovarian Yolk sac tumor: a case report and literature review. *Clin Case Rep Int.* 2018; 2: 1057.
- Alkatan HM, Al-Kofide A, Al-Hussain H. Yolk sac tumor: histopathologic report of 2 cases. *Can J Ophthalmol.* 2008; 43: 125-6.

10. van den Akker M, Vervloessem D, Huybrechs A, Declercq S, van der Werff Ten Bosch J. Yolk sac tumor in the abdominal wall of an 18-month-old girl: a case report. *J Med Case Rep.* 2017; 11: 47.
11. Khan IU, Jose J, Fawazy T, Hadi WA, Sharma PK. Testicular yolk sac tumor in an eight-month old child: a case report. *Gulf Med. J.* 2012; 1: 37-40.
12. Albany C, Einhorn L. Pitfalls in management of patients with germ cell tumors and slight elevation of serum alpha-fetoprotein. *J Clin Oncol.* 2014; 32: 2114-5.
13. Bokemeyer C, Nichols CR, Droz JP, Schmoll HJ, Horwich A, Gerl A, et al. Extragonadal germ cell tumors of the mediastinum and retroperitoneum: results from an international analysis. *J Clin Oncol.* 2002; 20: 1864-73.
14. AblinAR, Krailo MD, Ramsay NK, Malogolowkin MH, Isaacs H, Raney RB, et al. Results of treatment of malignant germ cell tumors in 93 children: A report from the Children's Cancer Study Group. *J Clin Oncol.* 1991; 9: 1782-92.
15. Devaney KO, Perlito A, Rinaldo A. Endodermal sinus tumor (yolk sac tumor) of the temporal bone: An exotic disease for otorhinolaryngologists and head and neck surgeons. *Acta Otolaryngol.* 2003; 123: 747-8.
16. McBee WC Jr, Brainard J, Sawady J, Rose PG. Yolk sac tumor of the ovary associated with endometrioid carcinoma with metastasis to the vagina: a case report. *Gynecol Oncol.* 2007; 105: 244-7.
17. Steinbacher DM, Upton J, Rahbar R, Ferraro NF. Yolk sac tumor of the mandible. *J Oral Maxillofac Surg.* 2008; 66: 151-3.