

Protection of the External Branch of the Superior Laryngeal Nerve in Transoral Endoscopic Thyroidectomy Vestibular Approach (TOETVA): An Observational Study

Wu Z^{1,2}, Fang J^{1*}, Ma H¹, Chen X¹, Zhong Q¹, Hou L¹, Huang J¹, Wang R¹ and Shen X¹

¹Thyroid Center, Beijing Tongren Hospital, Capital Medical University, Beijing 100730, P.R. China

²Department of Thyroid and Breast Surgery, Liaocheng People's Hospital, Liaocheng hospital affiliated to Shandong first medical university, Liaocheng 252000, Shandong, China

*Corresponding author:

Jugao Fang,
Thyroid Center, Beijing Tongren Hospital,
Capital Medical University, Beijing 100730,
P.R. China. E-mail: fangjugao2@ccmu.edu.cn

Received: 09 Apr 2021

Accepted: 27 Apr 2021

Published: 03 May 2021

Copyright:

©2021 Fang J. This is an open access article distributed under the terms of the Creative Commons Attribution License, which permits unrestricted use, distribution, and build upon your work non-commercially.

Citation:

Fang J. Protection of the External Branch of the Superior Laryngeal Nerve in Transoral Endoscopic Thyroidectomy Vestibular Approach (TOETVA): An Observational Study. *Ann Clin Med Case Rep.* 2021; V6(13): 1-6.

Keywords:

External Branch of the Superior Laryngeal Nerve; Transoral Endoscopic; Papillary Thyroid Cancer; Protection Function; Sternothyroid Muscle

1. Abstract

1.1. Background: Avoiding injury of the external branch of the superior laryngeal nerve (EBSLN) is one of the major challenges during thyroid surgery, especially in transoral endoscopic thyroidectomy vestibular approach (TOETVA). This study aimed to investigate the protective strategies of the EBSLN during TOETVA.

1.2. Methods: In order to protect the EBSLN during TOETVA, we adopted the method of identification the nerve by anatomy and localization. The method of anatomy involves the dissection of EBSLN by complete transection of the sternothyroid muscle in the attachment of the thyroid cartilage. The method of localization involves nerve stimulation localization, which produces cricothyroid contractile activity through intraoperative nerve monitoring stimulation (IONM). Concurrently, patients were evaluated preoperatively and at 1 and 3 weeks postoperatively in an individual prospective cohort study using a stroboscopic laryngoscope and the voice handicap index-10 (VHI-10). The VHI-10 score was used to evaluate voice changes.

1.3. Results: We retrospectively analyzed patients with papillary thyroid cancer (PTC) who underwent TOETVA in the thyroid center of the Beijing Tongren hospital between February 2018 and June 2020. Patients with recurrent laryngeal nerve (RLN) damage were excluded. Sixty patients were enrolled in this study, of which

four underwent total thyroidectomy. Intraoperatively, 56 EBSLNs were located (56/64, 87.50%). Among these, the left EBSLN was identified in 20/25(80.00%) and the right EBSLN was identified in 36/39 (92.31%) cases. One week postoperatively, a blinded stroboscopic laryngoscope examination showed that no patient had paresis of the EBSLN. However, the VHI-10 score was significantly higher than the preoperative value (10.58 ± 4.54 vs. 3.00 ± 1.54 , $p < 0.01$). At three weeks postoperatively, the overall score was still different from that preoperatively (4.83 ± 3.34 vs. 3.00 ± 1.54 , $p < 0.01$); however, the vast majority of patients returned to their preoperative status.

1.4. Conclusion: In TOETVA, the EBSLN can be well exposed by transection of the sternothyroid muscle, and combined with IONM, the protection of the function of the EBSLN can be guaranteed. Simultaneously, we observed that TOETVA could cause a short-term voice handicap in patients, with such changes generally returning to normal within three weeks.

2. Introduction

Due to the advantage of leaving no scars, transoral endoscopic thyroidectomy (TOET) gradually developed in China [1] and abroad and quickly became a hot research topic. Particularly, Anuwong [2] further added transoral endoscopic thyroidectomy vestibular approach (TOETVA) to our armamentarium. Reports

from high-volume thyroid surgeons have suggested that TOETVA is a safe and cosmetic alternative for well-selected patients [2-5]. However, there are still some inherent concerns related to TOETVA, including oncologic concerns of cancer seeding and local recurrence, the significant learning curve, and the potential for injury to the recurrent laryngeal nerve (RLN) or the mental nerve (MN) [6-8]. Meanwhile, there are fewer reports of the EBSLN during TOETVA [9-10]. Possibly, during TOETVA, the superior thyroid artery and vein are ligated as close to the thyroid as possible, and the EBSLN is preserved by avoiding its anatomical exposure [11]. However, the EBSLN is in closed anatomical proximity to the superior thyroid vessels and there is heterogeneity in the anatomy of the EBSLN. The EBSLN can be easily injured when the vessels of the superior thyroid are separated close to the gland, especially when it is difficult to expose the superior pole of the thyroid from the perspective of TOETVA surgery in a cephalic to caudal manner [12]. In addition, in endoscopic surgery, only an ultrasonic device can be used to cut off the blood vessels. When used blindly, thermal damage by the ultrasonic device may cause damage to the EBSLN. We believe that dissection to expose the EBSLN may provide better protection. However, surgical dissection to locate the EBSLN may result in unnecessary trauma and adversely affect voice quality. What are the more appropriate ways of protecting the EBSLN during TOETVA surgery? To address this question, this study was undertaken to identify the feasibility associated with a safe preservation of the EBSLN with transection of the sternothyroid muscle.

3. Materials and Methods

3.1. Patients This retrospective study was undertaken in the thyroid center of the Beijing Tongren hospital from February 2018 to June 2020. Inclusion criteria for patients followed the expert consensus of Chinese thyroid surgeons consisted of all patients diagnosed with papillary thyroid cancer by preoperative fine needle aspiration biopsy and those who underwent total thyroidectomy for bilateral micropapillary thyroid carcinoma. Exclusion criteria for this study included (1) patients with confirmed intraoperative injury of the RLN, and (2) patients who could not complete the follow-up task.

3.2. Surgical Technique

In this study, we completely transected the sternothyroid muscle near the attachment of the thyroid cartilage (Figure 1) and opened an avascular plane between the superior pole and the thyroid cartilage, which is called Joll's space [9] (Figure 2). In this space, the EBSLN could be identified beneath the thyroid suspensory ligament. Meanwhile, using intraoperative nerve monitoring stimulation (IONM) to stimulate the EBSLN at 1.0 mA, we assessed the cricothyroid muscle (CTM) twitch and electromyography (EMG) response. IONM was realized by connecting the nerve monitor wire with the electrocoagulation hook. We could safely continue to dissect and ligate the superior thyroid vessels. If the CTM twitching was weak and the estimation of the location of the EBSLN was difficult, we would ligate the superior thyroid artery and vein as close to the superior thyroid pole as possible.

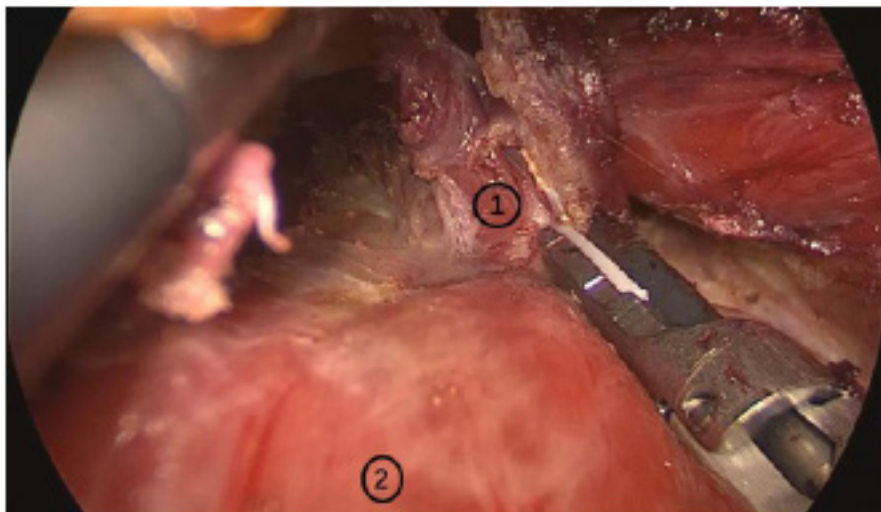


Figure 1: The sternothyroid muscle was transected at an attachment point on the thyroid cartilage, and was pushed to the sternal side, exposing the lobe of the thyroid gland. Here, ① represents the transverse sternothyroid muscle, and ② represents the thyroid gland lobe.

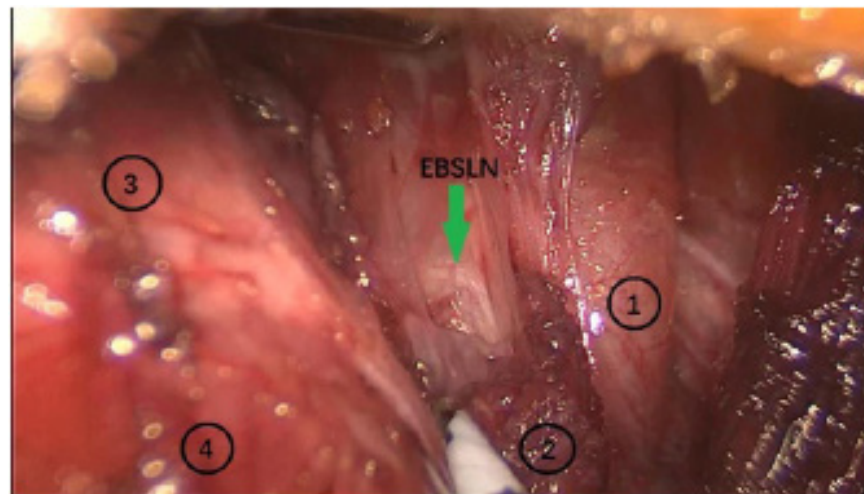


Figure 2: The thyroid gland was pulled outward and downward to expose Joll's space. In Joll's space, we looked for the EBSLN. ① is the superior polar gland of the thyroid; ② is the transverse sternothyroid muscle; ③ is the cricothyroid muscle (CTM) and ④ is the throat.

3.3. Objective Voice Analysis

Stroboscopic laryngoscopy was performed one week postoperatively, to further exclude any damage to the RLN and observe whether there was damage to the EBSLN. Patients with special symptoms were reevaluated three weeks later. We evaluated the voice changes in all patients using the voice handicap index-10 (VHI-10). Patients filled in the 10-item VHI-10 questionnaire [13]. The VHI-10 is one of the most psychometrically robust, well-studied, and efficient instruments among various instruments used to measure self-perceived voice related quality of life. The investigation time nodes were designed preoperatively, and at one and three weeks postoperatively.

3.4. Statistics

Statistical analysis was performed using SPSS 20.0 (IBM SPSS statistics 20.0.0; SPSS Inc, Chicago, IL). Continuous data are summarized as mean \pm interval of confidence 95%. Vocal motility was evaluated with the Student's t-test, for paired sample test on parametric variables. P values below 0.05 were considered significant.

4. Results

The data of 60 patients who underwent TOETVA were retrieved from the clinical database. All patients had papillary thyroid carcinoma and underwent central lymph node dissection. Four underwent total thyroidectomy and 56 underwent lobectomy. There were 50 females and 10 males, with an average age of 36.98 ± 9.27 years. Median operation time was 240.63 ± 66.39 min. Mean postoperative drainage volume was 111.79 ± 38.24 ml, and average postoperative hospital stay was 4.04 ± 1.35 days. The clinical data of all patients including postoperative complications are shown in **Table 1**.

In this study, left lobectomy was performed in 25 cases, and right lobectomy was performed in 39 cases. In all these 64 lobes, the EBSLN was identified in 56/64 cases (87.50%) and unidentified in 8/64 (12.50%) cases. Among these, the left EBSLN was identified in 20/25 (80.00%) and the right EBSLN was identified in 36/39 (92.31%) cases. CTM twitching was observed in all patients, and potentiometric wave images were present in some patients (**Figure 3**).

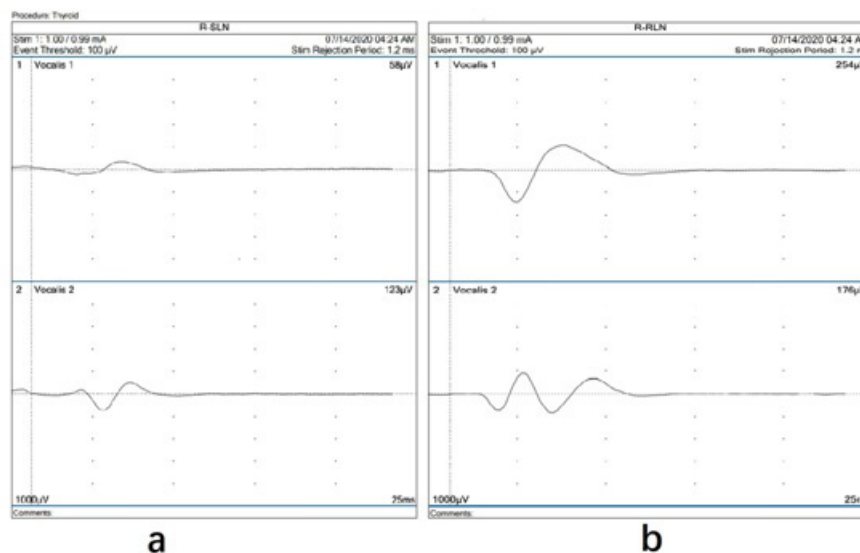


Figure 3: When IONM stimulated the EBSLN, CTM twitching was observed in all patients, and potentiometric wave images were present in some patients (see Figure 3a), and the waveform of the EBSLN was completely different from that of the RLN (see Figure 3b).

Table 1: demographic data and operative details

Characteristics and details	Value
Age (median, years)	36.98±9.27
Sex (male/female)	10/50
Tumor location (left lobe/right lobe)	21/39
Operation time (median, min)	240.63±66.39
Postoperative drainage (median, ml)	111.79±38.24
postoperative hospital stay (median, days)	4.04±1.35
Postoperative complication (cases)	
infection	1
seroma	1
Skin damage	1
Tracheal injury	0
Postoperative bleeding	0
Conjunctivitis	1
Permanent RLN palsy	0
Mental nerve injury	0
Permanent hypoparathyroidism	3

After completely transecting the sternothyroid muscle, the superior polar vessels of the thyroid could be severed under direct vision. Even the presence of superior pole vascular bleeding could be easily managed to avoid injury to the EBSLN (Figure 4).

The arrow in the figure indicates the EBSLN. One week postoperatively, stroboscopic laryngoscope monitoring showed that no

patients had changes in vocal cord tension. In all patients, the VHI-10 score was significantly higher than that of the preoperative value (10.58 ± 4.54 vs. 3.00 ± 1.54 , $p < 0.01$). After three weeks, the overall score was still different from that preoperatively (4.83 ± 3.34 vs. 3.00 ± 1.54 , $p < 0.01$); however, the vast majority of patients returned to their preoperative status (Table 2).

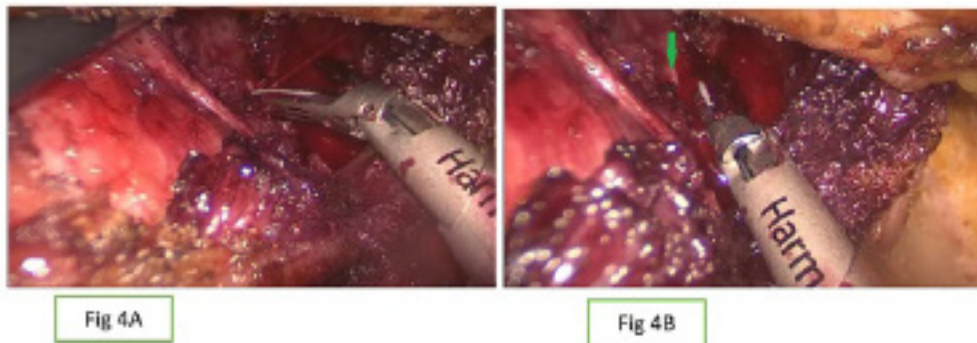
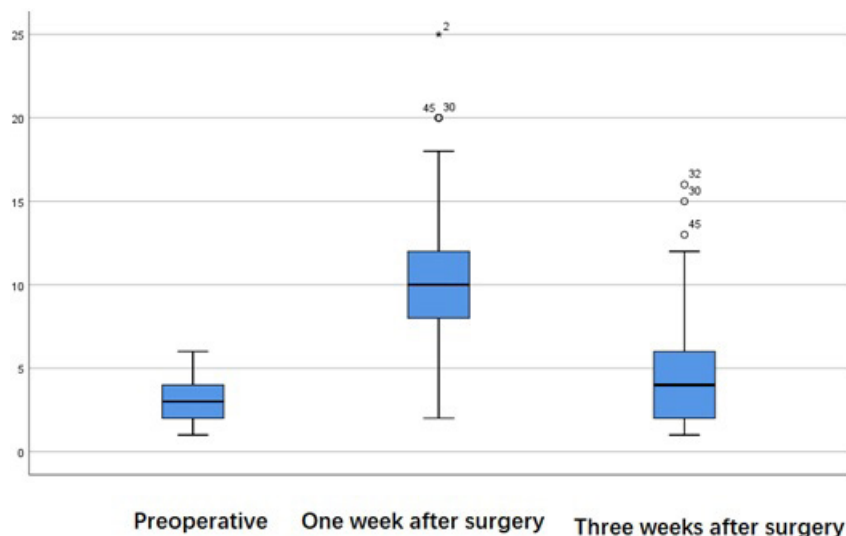


Figure 4: The bleeding point of the superior thyroid artery could be found under direct vision. The bleeding point could be clipped with an ultrasonic knife, and the non-functional head of the ultrasonic knife could be kept away from the EBSLN to avoid injury to the EBSLN.

Table 2: Three weeks postoperatively, the vast majority of patients returned to their preoperative status.



5. Discussion

Due to the angle of approach, it is difficult to expose the upper pole of the thyroid during TOETVA surgery, which may lead to the injury of the EBSLN. Moreover, EBSLN has an average diameter of only 0.8 mm [14] and is closely related to the vessels of the upper pole of the thyroid gland, which is prone to misbinding, thermal damage and even disconnection. The reported prevalence of EBSLN injury varies widely. It is reported in the literature that the EBSLN is injured in up to 58% of patients undergoing thyroidectomy [15]. Our previous study showed that in most cases (56%), the EBSLN is located close to the thyroid superior pole under physiological conditions, and it is prone to be injured during thyroid surgery [16]. However, EBSLN iatrogenic injury is considered the most commonly underestimated complication in thyroidectomy because vocal assessment underestimates such events and laryngoscopic postoperative evaluation does not show standardized findings [17]. Injury to the EBSLN can result in detrimental voice changes, which may impact the quality of voice with varying degrees of severity, which is more noticeable in professional voice users [18]. As the number of surgical patients, especially young women, increases every year, and postoperative quality of life becomes a major indicator of surgical success, more doctors realize that intraoperative protection of the EBSLN is as significant as that of the RLN. The protection of the EBSLN is very justified. Recently, IONM provides multiple advantages in the EBSLN surgical approach. Several studies demonstrated that IONM was a more effective method than traditional visualization in localizing the EBSLN [19]. During EBSLN stimulation, CTM twitching is noted in patients. Therefore, some scholars have proposed that the process of dissecting exposed EBSLN may cause nerve damage, and the IONM region protection method can be used to protect the EBSLN. Close to the gland, the vessels in the upper pole of the thyroid are manipulated as if removing a hat [12]. We believe that the treatment of the superior pole vessels closely attached to the gland may result in residual glands or inaccurate treatment of the superior pole vessels, resulting in postoperative bleeding. Furthermore, the use of a simple clingy gland treatment may also result in the disconnection of the EBSLN or in thermal damage by the ultrasonic scalpel. In particular, in some patients with superior pole vascular bleeding, such as the patients mentioned in this article, only the dissection of the EBSLN can avoid injury. During surgery, we would cut off the sternothyroid muscle in the attachment of the thyroid cartilage, while pushing the muscle stump toward the head with the ultrasonic knife, concurrently, pulling the upper pole outwards and down with the uninjured grasping forceps. After sufficient separation of the body of the larynx from the superior polar gland, the EBSLN is usually exposed in an avascular area. The exposure rate of the EBSLN in our data was 87.50%; and the right EBSLN was more exposed. We found that the anatomical exposure of the EBSLN could permit a safer manipulation of

the superior pole vessels, even with hemorrhage of the superior pole vessels, it could be clipped safely and avoided injury to the EBSLN. At the same time, pushing the transverse sternothyroid muscle to the side of the sternum can better expose the thyroid gland and lymph nodes in the central region, which is conducive for lymph node dissection in the central region. Previous studies have confirmed that the disconnection of the sternothyroid muscle has no effect on sound changes after thyroid surgery [20]. IONM provides regional protection for hard-to-view EBSLN. Cricothyroid muscle tremor was observed with 1 mA stimulation to indicate the location of the EBSLN. Our data shows that it is better to use both methods to protect the EBSLN. The steps to protect the EBSLN were outlined in the 2013 guidelines [14]: ① Expose of the space harboring the EBSLN; ② Bluntly dissect the tissues; ③ Stimulate the tissues during dissection; ④ Look for a cricothyroid twitch; ⑤ Navigate your dissection using the technique of nerve mapping. In addition, we found that after thyroid surgery, patients might present with pronunciation discomfort for a variety of reasons, possibly due to surgical stimulation or drainage tube placement. The VHI-10 score was significantly higher 1 week postoperatively than the preoperative values. However, most patients returned to normal after 3 weeks. In our study, stroboscopic laryngoscope monitoring showed that no patients had changes in vocal cord tension.

6. Conclusion

In TOETVA, the EBSLN can be well exposed by transection of sternothyroid muscle, and combined with IONM, the function of the EBSLN can be well protected. At the same time, we observed that TOETVA could cause short-term voice handicap in patients, with such changes generally returning to normal within three weeks. My paper is supported by the Capital Health Research and Development of Special (Grant No. 2018-2-2054); meanwhile, this paper is supported by Wu Jieping Medical Foundation (Grant No. 320.6750.18229)

Reference

1. Wang C, Zhai H, Liu W, Li J, Yang J, Hu Y, et al. Thyroidectomy: A novel endoscopic oral vestibular approach. *Surgery*. 2014; 155(1): 33-38.
2. Anuwong A. Transoral Endoscopic Thyroidectomy Vestibular Approach: A Series of the First 60 Human Cases. *World J Surg*. 2016; 40(3): 491-497.
3. Liu Z, Peng X, Li Z, Zhou B, Wu P, Lv C, et al. Postoperative drain after transoral endoscopic thyroidectomy vestibular approach (TOETVA) with single incision. *Surg Endosc*. 2021; 35: 1-9.
4. Anuwong A, Ketwong K, Jitpratoom P, Sasanakietkul T, Duh Q. Safety and Outcomes of the Transoral Endoscopic Thyroidectomy Vestibular Approach. *JAMA Surgery*. 2017. 153(1): 21-27.
5. Russell J O, Anuwong A, Dionigi G, Inabnet WB, Kim HY, Randolph G, et al. Transoral Thyroid and Parathyroid Surgery Vestibular

- Approach: A Framework for Assessment and Safe Exploration. *Thyroid*. 2018; 28(7): 825-829.
6. Yeh Y, Chen J, Kuo P, Wang T, Lee H, Chi C, et al. Printing a Three-Dimensional Patient-Specific Safety Device for Reducing the Potential Risk of Mental Nerve Injury During Transoral Thyroidectomy. *World J Surg*. 2020; 44(2): 371-377.
 7. Zhang D, Fu Y, Dionigi G, Pontin A, Caruso E, Antonella P, et al. Human cadaveric model for studying the preservation of mental nerve during transoral endoscopic thyroidectomy. *Surg Radiol Anat*. 2020; 42(1): 55-62.
 8. Camenzuli C, Wismayer P S, Agius J C. Transoral Endoscopic Thyroidectomy: A Systematic Review of the Practice So Far. *JSLs*. 2018; 22(3): e2018.00026.
 9. Anuwong A, Sasanakietkul T, Jitpratoom P, Ketwong K, Kim HY, Dionigi G, et al. Transoral endoscopic thyroidectomy vestibular approach (TOETVA): indications, techniques and results. *Surg Endosc*. 2018; 32(1): 456-465.
 10. Zhang D, Park D, Sun H, Anuwong A, Tufano R, Kim Hy, et al. Indications, benefits and risks of transoral thyroidectomy. *Best Pract Res Clin Endocrinol Metab*. 2019; 33(4): 101280.
 11. Bellantone RD, Boscherini M, Lombardi CP, M Bossola, F Rubino, C De Crea, et al. Is the identification of the external branch of the superior laryngeal nerve mandatory in thyroid operation? Results of a prospective randomized study. *Surgery*. 2001; 130(6): 1055-1059.
 12. Zhang D, Wang T, Kim H, Wang P, Dionigi G, Pino A, et al. Strategies for superior thyroid pole dissection in transoral thyroidectomy: a video operative guide. *Surgical Endoscopy*. 2020; 34(8): 3711-3721.
 13. Delgadovargas B, Romerosalazar AL, Cobeta I. Vocal Changes Following Thyroid Surgery: Prospective Study of Objective and Subjective Parameters. *J Voice*. 2017; 33(1): 27-32.
 14. Barczynski M, Randolph GW, Cernea CR, Dralle H, Dionigi G, Alesinae PF, et al. External branch of the superior laryngeal nerve monitoring during thyroid and parathyroid surgery: International Neural Monitoring Study Group standards guideline statement. *Laryngoscope*, 2013; 123 Suppl 4: S1-14.
 15. Cheruiyot I, Kipkorir V, Henry BM, Munguti J, Ciocchi R, Odula P, et al. Surgical anatomy of the external branch of the superior laryngeal nerve: a systematic review and meta-analysis. *Langenbeck's Archives of Surgery*. 2018; 403(7): 811-823.
 16. Ma Hongzhi, Fang Jugao, Hou Lizhen, et al. Study on the Physiological Anatomy and Function Protection of EBSLN during Thyroid Surgery. *Int J Otolaryngol Head Neck Surg*, 2020, 44(01):1-5. in Chinese
 17. Alberto M, Lianos G D, Luigi B, Kim HY, Roukos DH, Dionigi G. Intraoperative Neuromonitoring of the External Branch of the Superior Laryngeal Nerve during Thyroidectomy: The Need for Evidence-Based Data and Perioperative Technical/Technological Standardization. *Scientific World Journal*. 2014; 2014: 854-5.
 18. Friedman M, Losavio P, Ibrahim H. Superior Laryngeal Nerve Identification and Preservation in Thyroidectomy. *Archives of Otolaryngology-head & Neck Surgery*. 2002; 128(3): 296-303.
 19. Wang K, Cai H, Kong D, Cui Q, Zhang D, Wu G. The Identification, Preservation and Classification of the External Branch of the Superior Laryngeal Nerve in Thyroidectomy. *World Journal of Surgery*. 2017; 41(10): 2521-2529.
 20. Henry L R, Solomon N P, Howard R S, Gurevich-Uvena J, Horst LB, Coppit G, et al. The functional impact on voice of sternothyroid muscle division during thyroidectomy. *Annals of Surgical Oncology*, 2008, 15(7): 2027-2033.