

## Recurrent Carcinosarcoma of the Breast: A Case-Report

Sompornpailin N<sup>1</sup> and Teeyapun N<sup>2\*</sup>

<sup>1</sup>Department of Medicine, Faculty of Medicine, King Chulalongkorn Memorial hospital and Chulalongkorn University

<sup>2</sup>Division of Medical Oncology, Department of Medicine, Faculty of Medicine, King Chulalongkorn Memorial hospital and Chulalongkorn University

### \*Corresponding author:

Nattaya Teeyapun,  
Department of Medicine, Faculty of Medicine,  
King Chulalongkorn Memorial hospital and  
Chulalongkorn University, Thailand,  
E-mail: na2672000@gmail.com;  
amprabbit@yahoo.co.th

Received: 01 Jun 2021

Accepted: 19 Jun 2021

Published: 24 Jun 2021

### Copyright:

©2021 Teeyapun N. This is an open access article distributed under the terms of the Creative Commons Attribution License, which permits unrestricted use, distribution, and build upon your work non-commercially.

### Citation:

Teeyapun N, Recurrent Carcinosarcoma of the Breast: A Case-Report. Ann Clin Med Case Rep. 2021; V6(18): 1-5

### Keywords:

Metastatic carcinosarcoma; Triple-negative breast cancer; Chest wall tumor

## 1. Abstract

Carcinosarcoma or metaplastic carcinoma of the breast with mesenchymal differentiation classified as subtypes of metaplastic breast carcinoma (MBC) is a rare and highly aggressive tumor. Metastasis to soft tissue and bone is a challenging issue to make a diagnosis because of similarity to the mesenchymal tumor.

This clinical data reported female patient presenting with rapidly growing chest wall mass and immunohistochemistry revealed metastatic carcinosarcoma which distinguish from other mesenchymal tumors.

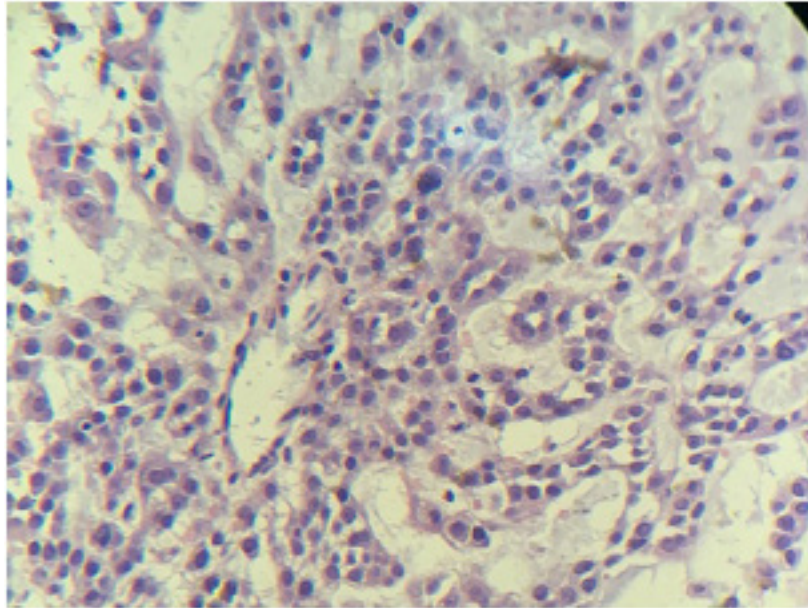
## 2. Introduction

Carcinosarcoma of the breast is a rare and highly aggressive tumor that occurs for 0.25-1% of all breast cancers diagnosed annually [1]. Mean age of diagnosis is fifth to sixth decade of life. Histopathologically, carcinosarcoma is a poorly differentiated cancer that is composed of a mixture of carcinoma cells and nonepithelial mesenchymal components that included elements of chondroid, osteoid, rhabdomyoid and neuroglial differentiation[2]. According to W.H.O. classification of tumors of the breast published in 2012, Carcinosarcoma is one of the five distinct subtypes of metaplastic breast cancer which other subtypes include squamous cell carcinoma, low-grade adenosquamous carcinoma, spindle cell carcinoma, and fibromatosis-like metaplastic carcinoma [3].

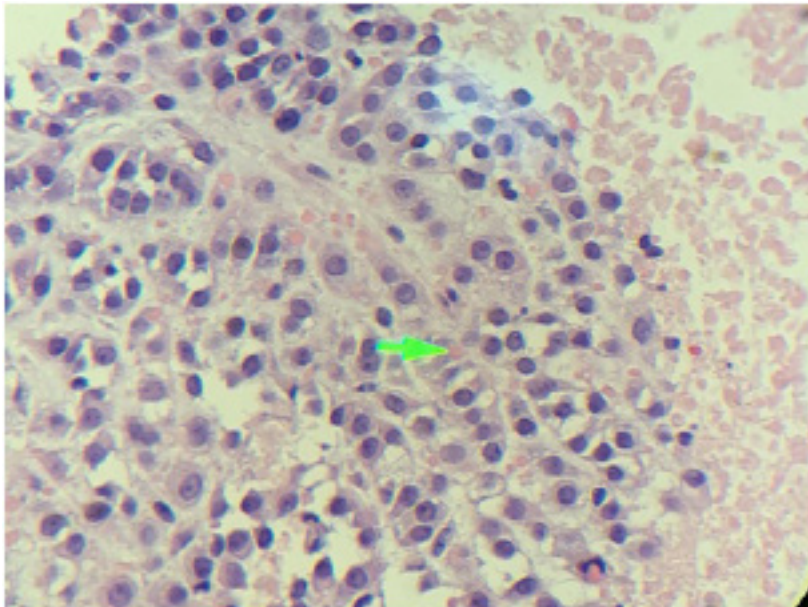
This cancer is usually triple-negative [4] but hormone receptor status does not appear to affect prognosis [5], the prognosis is worse due to present with a more advanced stage at diagnosis. Lung and pleural metastases are the most common site [6]. The systemic therapy also appears to be less effective [7].

## 3. Case Report

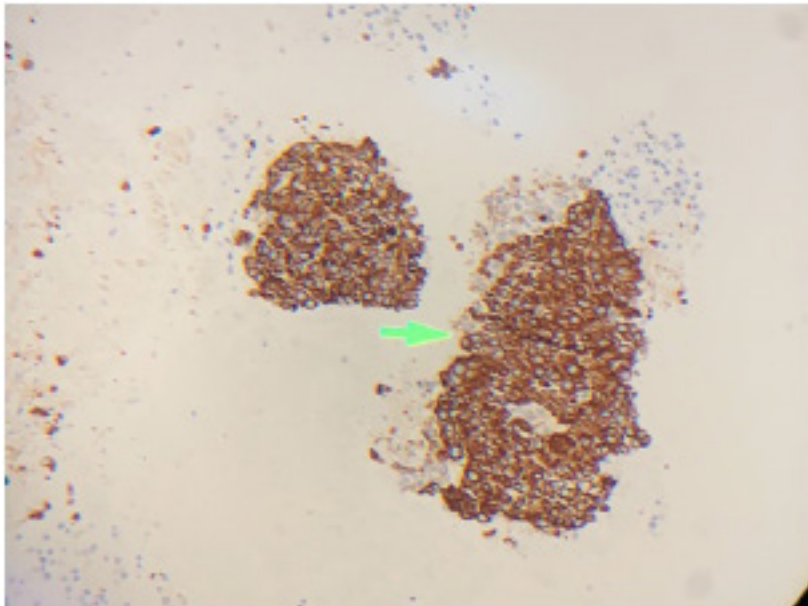
A 49-year-old female was previously diagnosed with stage II (pT-2N0M0) grade III invasive ductal carcinoma of the left breast with triple-negative phenotype in 2012. She underwent left modified radical mastectomy and was treated with FAC (Fluorouracil/Doxorubicin/cyclophosphamide) regimen as an adjuvant chemotherapy. After two years, she found 1 cm right breast mass by annual breast examination, and core needle biopsy showed invasive ductal carcinoma grade III. Accordingly, modified radical mastectomy was also done on right breast. In November 2019, she noticed a soft mass on the middle of her chest wall which gradually increased in size. She denied any symptom of chest discomfort or tenderness. MRI showed 10.0x4.8x5.6 cm soft tissue enhancing mass with hypointense SI on T1W and hyperintense SI on T2W at anterior upper chest wall which destroyed manubrium and body of the sternum. Mass invaded to anterior and superior mediastinum space and encased SVC. She denied treatment and sought for alternative medicine (Figure 1-8).



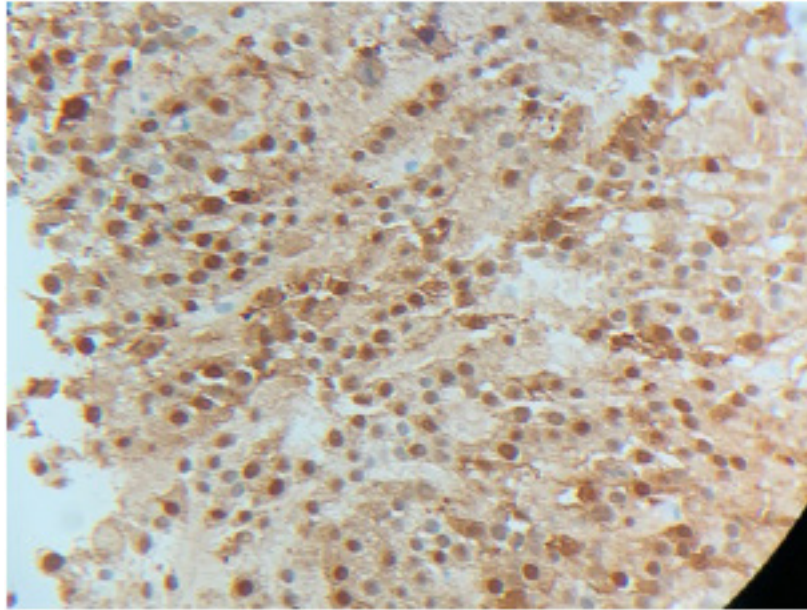
**Figure 1:** H&E of chest wall mass, epithelioid cell neoplasm cells are arranged in cord and trabecular patterns with myoid stroma



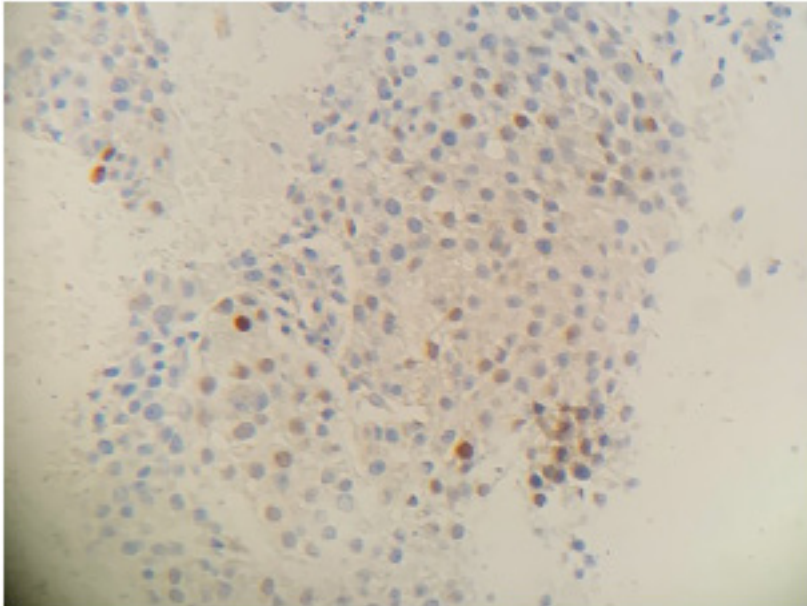
**Figure 2:** H&E of chest wall mass, epithelioid cell neoplasm cells are arranged in cord and trabecular patterns with myoid stroma



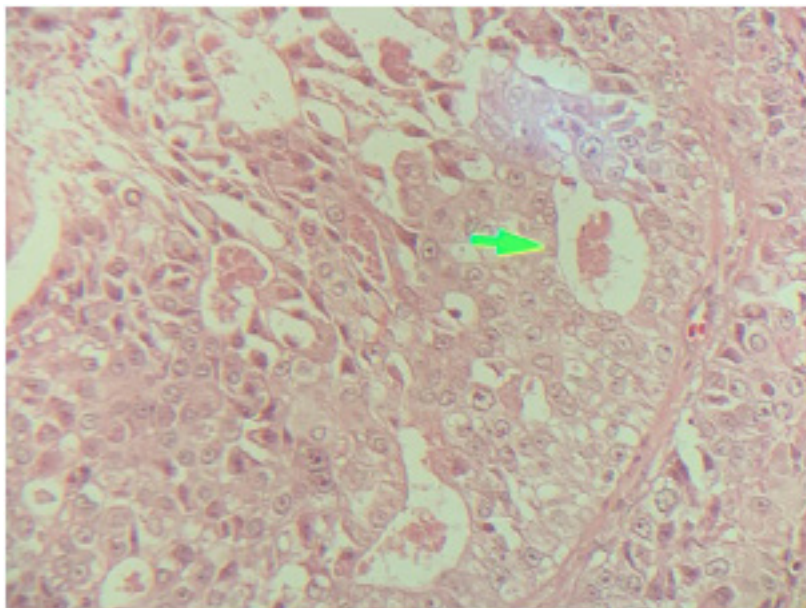




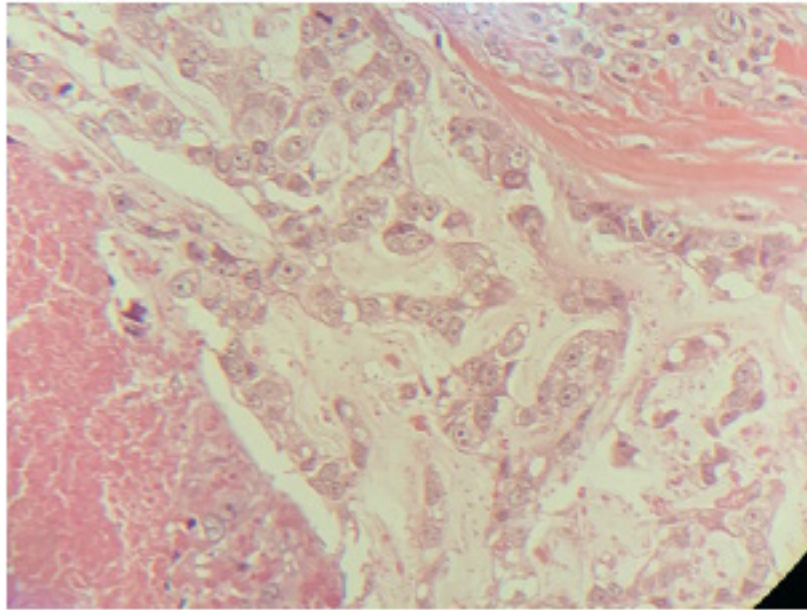
**Figure 4:** IHC of chest wall mass, positive for S100



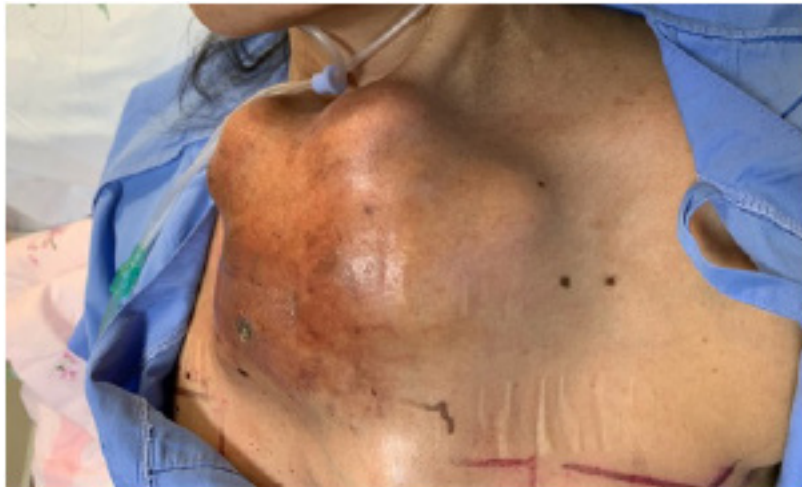**Figure 5:** IHC of chest wall mass, positive for GATA3



<http://acmcasereports.com/> **Figure 6:** H&E of right breast tissue, invasive ductal carcinoma



**Figure 7:** H&E of right breast tissue, epithelioid cell neoplasm cells are arranged in cord and trabecular patterns with myoid stroma



**Figure 8:** chest wall mass

In March 2020, two months prior to admission, she came back to our hospital and first biopsy of chest wall mass was performed. Tissue histopathology reported epithelioid cell neoplasm infiltrating the intertrabecular spaces, tumor cells are arranged in cord and trabecular patterns with myoid stroma. The immunohistochemistry showed diffusely positive S100, Vimentin, and collagen type IV (stain around nests of cells), focally positive for AE1/AE3, CAM5.2, and negative for Arginase-1, Glypican3, HepPar-1, TTF1, p40. The differential diagnosis was parachordoma, mesenchymal chondrosarcoma, and metastatic carcinosarcoma.

Two weeks prior to admission, she her dyspneic symptom became worse and persisted even at rest. She could not lie down and her face gradually swollen. She visited King Chulalongkorn Memorial hospital and was admitted.

At admission, chest computerized tomography scan revealed a 10.1x13.4x16.1-cm lobulated heterogeneous enhancing anterior mediastinal mass with associated bony destruction of manubrium, sternum, tumor thrombi of all segmental branches of pulmonary

<http://acmcasereports.com/>

arteries, SVC. Innumerable various-sized of pulmonary nodules scattered in both lungs. SVC syndrome with tumor thrombi of pulmonary arteries with pulmonary metastases was diagnosed. Second biopsy of chest wall mass showed malignant epithelioid neoplasm with chordoma like pattern. The immunohistochemistry showed 50-60% positive for S100, 5- 10% positive for AE1/AE3 in general area and focal densely in solid area and positive for GATA3 focal densely in solid area which represented chest wall tissue was originated from breast tissue. The review of previous right breast tissue revealed epithelioid cell neoplasm cells are arranged in cord and trabecular patterns with myoid stroma is also present focally. Finally, metastatic carcinosarcoma was concluded as diagnosis after immunohistopathology and clinical data was incorporated.

Plan of treatment was carefully discussed with patient and her relatives. Eventually, she did not receive any systemic therapy due to limited performance status and received palliative radiotherapy at chest wall mass for pain relieving.

#### 4. Discussions

Our reported case was finally diagnosed recurrent carcinosarcoma of the breast with chest wall and pulmonary metastases. Tissue histopathology reported epithelioid cell neoplasm which arranged in cord and trabecular patterns with myoid stroma. The immunohistochemistry was done to distinguish the types of tumor included parachordoma, mesenchymal chondrosarcoma and metastatic carcinosarcoma. Positive for S100, EMA, Collagen type 4, and vimentin supported parachordoma and carcinosarcoma which is almost always found these IHC stains while 50% of mesenchymal chondrosarcoma were positive for S-100 protein and EMA [8].

However, GATA3 focal densely in solid area which represented chest wall tissue was originated from breast tissue and the review of previous right breast tissue revealed epithelioid cell neoplasm arranged in cord and trabecular patterns.

Immunohistochemistry showed negativity of hormone receptors (ER and PR), Her-2 and high Ki-67 which consistent with report in the previous literature [9].

Additionally, the aggressive manifestation of tumor that caused rapidly growing chest wall mass, pulmonary metastases, and tumor thrombi that commonly present in carcinosarcoma of breast. All evidences of tissue histopathology, immunohistochemistry are compatible with metastatic carcinosarcoma at chest wall originated from previous right breast cancer.

In terms of treatment, there is rarity of evidence for systemic treatment of this cancer type, most of clinical practice use chemotherapy which recommended for invasive breast cancer. The response rate of first line chemotherapy ranging from only 8-18% [9] and favor taxane-base regimen. However poor response to chemotherapy, this tumor has trend to have EGFR (Epidermal Growth Factor Receptor) expression in almost 70% of the cases that might be benefit for EGFR targeting therapy.

#### 5. Conclusion

Metastatic carcinosarcoma at chest wall with histopathology of the mesenchymal tumor is difficult to diagnose and poor treatment response with standard chemotherapy for classical invasive ductal carcinoma. Multi-disciplinary approach is necessary for discussion using clinical contexts, histopathology, immunohistochemistry result.

#### References

1. Leddy R, Irshad A, Rumboldt T, Cluver A, Campbell A, Ackerman S. Review of metaplastic carcinoma of the breast: imaging findings and pathological features. *J Clin Imaging Sci.* 2012; 2(1): 21.
2. Kennedy WR, Gabani P, Acharya S, Thomas MA, Zoberi I. Clinical outcomes and patterns of care in the treatment of carcinosarcoma of the breast. *Cancer Med.* 2019; 8(4): 1379-1388.
3. Reis-Filho JS, Lakhani SR, Gobbi H, Sneige N. Metaplastic carcinoma. In: Lakhani S, Ellis I, Schnitt S, eds. *World Health Organization Classification of Tumours of the Breast*, 4th edn. Lyon: IARC Press; 2012: 48-52.

4. Yerushalmi R, Hayes MM, Gelmon KA. Breast carcinoma—rare types: review of the literature. *Ann Oncol* 2009; 20: 1763-70.
5. Bae SY, Lee SK, Koo MY, Hur SM, Choi M, Cho DH, et al. The prognoses of metaplastic breast cancer patients compared to those of triple-negative breast cancer patients. *Breast Cancer Res Treat.* 2011; 126: 471-8.
6. Chao TC, Wang CS, Chen SC, Chen MF. Metaplastic carcinomas of the breast. *J Surg Oncol.* 1999 Aug;71(4):220-5
7. Rayson D, Adjei AA, Suman VJ, Wold LE, Ingle JN. Metaplastic breast cancer: prognosis and response to systemic therapy. *Ann Oncol.* 1999; 10(4): 413-419.
8. Folpe AL, Agoff SN, Willis J, Weiss SW. Parachordoma is immunohistochemically and cytogenetically distinct from axial chordoma and extraskelatal myxoid chondrosarcoma. *Am J Surg Pathol.* 1999; 23(9): 1059-67.
9. Salemis NS. Metaplastic carcinoma of the breast with mesenchymal differentiation (carcinosarcoma). A unique presentation of an aggressive malignancy and literature review. *Breast disease.* 2018; 37(3): 169-75.