

Effect of Inhaled Nitric Oxide on Acute Cor Pulmonale in Covid-19 Pneumonia Associated Acute Respiratory Distress Syndrome; A Case Report

Ichikawa Y¹, Maruo H¹, Motoyama H¹, Shono A¹, Somei M¹, Ohsugi K¹, Watanabe T¹, Kimura T², Mori M¹, Kikuyama K¹ and Kotani T^{1*}

¹Department of Intensive Care Medicine, Showa University, Tokyo, Japan

²Division of Respiratory Medicine and Allergology, Department of Medicine, Showa University, Tokyo, Japan

*Corresponding author:

Toru Kotani,
Department of Intensive Care Medicine, Showa
University School of Medicine, 1-5-8,
Hatanodai, Shinagawa-ku, Tokyo 142-8666,
Japan, Tel: +81-3-3784-8575,
Fax: +81-3784-8357,
E-mail: torukotani@gmail.com

Received: 09 Jun 2021

Accepted: 24 Jun 2021

Published: 29 Jun 2021

Copyright:

©2021 Kotani T. This is an open access article distributed under the terms of the Creative Commons Attribution License, which permits unrestricted use, distribution, and build upon your work non-commercially.

Citation:

Kotani T, Effect of Inhaled Nitric Oxide on Acute Cor Pulmonale in Covid-19 Pneumonia Associated Acute Respiratory Distress Syndrome; A Case Report. *Ann Clin Med Case Rep.* 2021; V6(19): 1-4

Abbreviations:

ACP: Acute cor pulmonale; APRV: Airway pressure release ventilation; APTT: Activated prothrombin time; ARDS: Acute respiratory distress syndrome; COVID-19: Coronavirus disease 2019; ECMO: Extracorporeal membrane oxygenation; iNO: Inhaled nitric oxide; LV: Left ventricular; PEEP: Positive end-expiratory pressure; P/F: PaO₂ to FIO₂ ratio; PH: Pulmonary hypertension; RV: Right ventricular; TTE: Transthoracic echocardiography

Author's contributions:

YK and HM carried out data collection and ultrasound testing. HM, MS, KO, MM, KK, TKi and TW were responsible for patient care. TKo and AS were major contributors in writing manuscript. All authors read and approved the final manuscript.

Keywords:

Nitric Oxide; Coronavirus disease 2019; Acute Respiratory Distress Syndrome; Acute Cor Pulmonale

1. Abstract

1.1. Background

Theoretically, inhaled nitric oxide can be effective on the treatment of acute cor pulmonale. However, the efficacy during acute respiratory distress syndrome has not been proved.

1.2. Case

A 64-year-old man who had medical history including asthma and hyperuricemia admitted and mechanically ventilated due to Coronavirus disease 2019 associated acute respiratory distress syndrome. The patient required veno-venous extracorporeal membrane oxygenation with 16-hour prone positioning and continuous neuromuscular blockade. Anticoagulation therapy was difficult throughout the treatment course. On ICU-day 25, hypotension and tachycardia were observed and ultrasound testing suggested the development of acute cor pulmonale. The patient was successfully weaned from extracorporeal membrane oxygenation on day 47,

but another episode of acute cor pulmonale occurred and it was refractory to all treatment measures except inhalation of 20 ppm of nitric oxide. Inhaled nitric oxide was terminated two weeks later and the patient survived.

1.3. Conclusion

Our experience encourages to use nitric oxide inhalation as a rescue measures to alleviate symptoms of acute cor pulmonale

2. Introduction

Coronavirus disease 2019 (COVID-19), which has been prevalent around the world since the end of 2019, is associated with diffuse lung injury and acute respiratory distress syndrome (ARDS). High incidence of thromboembolism was found by autopsy in COVID-19 positive patients [2]. It is reported that right ventricular (RV) failure and acute cor pulmonale (ACP) as complications of mechanical ventilation occur in up to 50% of ARDS patients [6]. Thromboembolism in the lung microcirculation caused by

COVID-19 can increase the risk of pulmonary hypertension (PH) and RV failure. Though the treatment of RV failure including optimization of preload, management of mechanical ventilation to reduce right ventricular afterload, pulmonary vasodilation, and use of inotropic agents has been performed, the mortality rate when complicated with ARDS is still high [1]. Theoretically, inhaled nitric oxide (iNO) can be effective on PH induced RV failure and acute cor pulmonale. However, the efficacy on RV failure during ARDS has not been proved.

We report a case in which iNO played a role in alleviating symptoms of ACP that developed during the treatment of ARDS caused by COVID-19 associated pneumonia.

3. Case

A 64-year-old man had been aware of fever, appetite loss, nausea, and back pain 10 days before this admission. His medical history included asthma and hyperuricemia. The patient visited a general hospital because of dyspnea and polymerase chain reaction testing confirmed COVID-19 infection positive. Since respiratory condition progressively deteriorated, the patient was intubated and mechanically ventilated 3 days before the admission. Bilateral ground glass opacity, exclusion of cardiogenic pulmonary edema, and PaO₂ to FIO₂ ratio (P/F) of 79.8 mmHg at positive end-expiratory pressure (PEEP) of 15cmH₂O confirmed the diagnosis as severe ARDS. Oxygenation kept going worse after intubation and the patient was transferred to our hospital to assess the use of extracorporeal membrane oxygenation (ECMO).

On admission arterial blood gas analysis showed; pH 7.444, PaO₂ 63 mmHg, PaCO₂ 47 mmHg, bicarbonate 31.5 mmol/L with FIO₂ of 1.0. The temperature was 37.2°C, the heart rate 117 beats per minute, the blood pressure 92/69 mmHg, respiratory rate 30/min.

Prone positioning on ICU-day 1 improved oxygenation to 150 mmHg, but it was not sustained after returning to supine position. The driving pressure required 19 cmH₂O for CO₂ elimination because of low respiratory compliance and expiratory flow limitation. Therefore, veno-venous ECMO was started with 16-hour prone positioning and continuous neuromuscular blockade from ICU-day 2. Evaluation of homogeneity of regional ventilation using electrical impedance tomography showed airway pressure release ventilation (APRV) with Phigh of 27 cmH₂O, Thigh of 7 seconds, and auto-release at 75% of peak expiratory flow rate could provide the best homogeneity and the largest end-expiratory lung volume compared to other settings. Heparin was started to adjust activated prothrombin time (APTT) in the range of 40 and 45 seconds for anticoagulation therapy during ECMO, but APTT stayed around 26-35 seconds despite the dose of heparin was increased up to 25,000 to 35,000 units/day. D-dimer reduced to 20-40 µg/ml after heparin administration but did not return to the normal level (Figure 1).

Hemodynamics had been stable since admission. On ICU-day 25, however, systolic blood pressure suddenly decreased to 60mmHg with the heart rate of 120-130 beats/min. The transthoracic echocardiography (TTE) showed that the estimated RV pressure was 89.7 mmHg. RV expansion and left ventricular (LV) D-shape were also observed. These were compatible with RV pressure load. Additionally, acute renal failure and liver congestion were accompanied, indicating acute cor pulmonale developed. After the support of inotropes, dobutamine and milrinone, RV function improved. Hemodynamics restored and dobutamine was withdrawn. Although carbon dioxide elimination was still impaired, oxygenation was stabilized and the patient was weaned from ECMO on ICU-day 47.

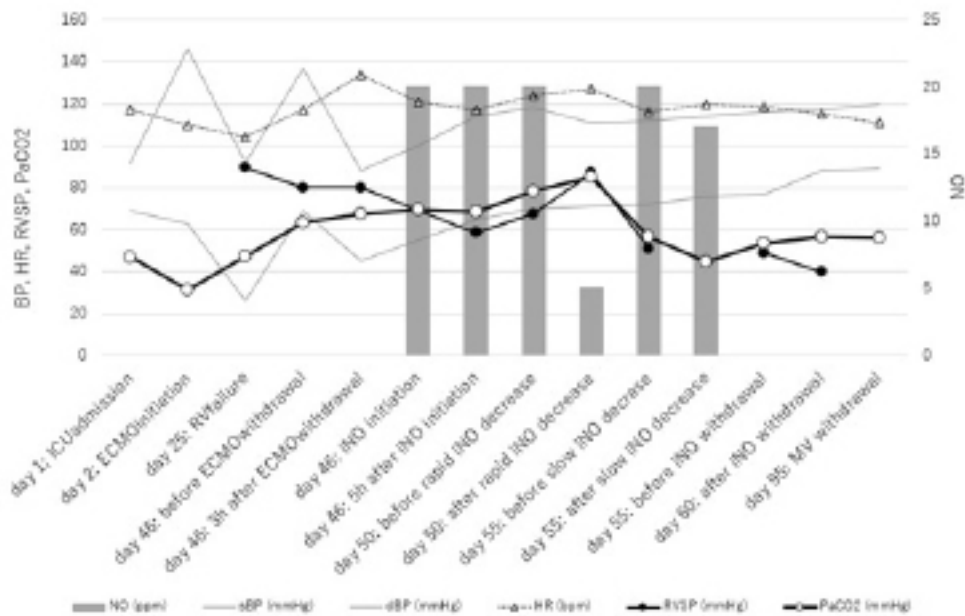


Figure 1

In a few hours after the weaning from ECMO, tachycardia more than 140 beats/min appeared accompanied with mild deterioration of gas exchange. TTE found PH with the estimated RV pressure of 80 mmHg, RV expansion and LV D-shape similar as seen before. Although inotropic agents with equal or higher dose administered again, PH was not alleviated. Therefore, inhaled nitric oxide (iNO) was added with the increasing dose up to 20 ppm. iNO did not decrease the estimated RV pressure, but RV expansion and LV D-shape disappeared more quickly than the previous event. No further positive effect was observed when the dose increased up to 40 ppm. After confirming the decrease in RV pressure load on ICU-day 50 we decreased iNO from 40 to 5 ppm, resulted in RV pressure load instantly. We increased to 20ppm again and gradually reduced by 1 to 5ppm every 6 hours. On ICU-day 60 iNO and inotropic agents were successfully discontinued. Estimated

RV pressure was 40 mmHg. Hemodynamic parameters were not different compared to previous rapid termination, but PaCO₂ was lower (Figure 1).

Anticoagulation therapy was difficult throughout the treatment course. We changed the artificial lung twice during 46-day ECMO run. The chest CT scan was taken on ICU-day 41, 54, 82 (without contrast), and 72 (with contrast) and no apparent feature of pulmonary thromboembolism was detected. After ECMO withdrawal APTT returned around 30 seconds and D-dimer reduced from 20 µg/ml to 3-5 µg/ml. Heparin of 10000U/day was continued for DVT prophylaxis and was switched to oral Edoxaban of 60mg 7 days later. Before and after the change from heparin to Edoxaban, both APTT and D-dimer did not change (Table 1).

The patient was weaned from mechanical ventilation on ICU-day 95 and discharged from ICU on day 116.

Table 1: Anticoagulation therapy and coagulation profile.

ICU-day	1	2	25	46	50	52	53	54	55	56	57	60	94
D-dimer (µg/mL)	159.5	121.0	21.57	23.1	4.0	4.7	5.8	4.9	4.7	4.0	4.3	3.6	5.2
APTT (sec)	28.0	30.0	49.5	47.2	28.2	27.9	27.6	27.2	27.2	30.0	31.0	31.6	28.0
Heparin (U/day)	0	25000	35000	35000	10000	10000	10000	10000	10000				
Edoxaban (mg/day)										60	60	60	

4. Discussion

There are few reports on RV failure in COVID-19 pneumonia [5, 6]. A report demonstrated that COVID-19 caused extensive microvascular thromboembolism and angiogenesis in the alveoli capillaries [2], leading to the increased pulmonary vascular resistance and RV failure. This is supported by the increased values of D-dimer and the difficulties in controlling APTT (Table 1). In COVID-19 associated ARDS, although radiological test did not detect the evidence, it is possible that thromboembolism in the pulmonary capillaries promotes PH or adds additional mechanism to conventional mechanisms of PH in ARDS.

It is reported that RV failure occurs in 50% of ARDS patients [1] and is an independent determinant of mortality [9]. Early diagnosis and treatment are necessary to prevent RV failure. RV function are usually evaluated by measures using TTE or transesophageal echocardiography (TEE) in the ICU. Evaluation using ultrasound technique, however, is still controversial. Using pulmonary artery catheter is a standard technique to evaluate RV function and the effect of treatment, but it is not recommended in ARDS patient because there are risk of bleeding, infection, and direct injury by the catheter. If tricuspid valve regurgitation with RV expansion exists, pressure measurement goes inaccurate. Taken together, TTE is acceptable to evaluate pulmonary artery pressure and to diagnose RV failure in this case.

Hypercapnia is one of the risk factors of ACP in ARDS patients ventilated with lung protective strategy [3]. It is proposed that

PaCO₂ is maintained less than 60 mmHg to prevent ACP [8]. When the first event of ACP was observed, PaCO₂ was 67 mmHg and increased up to 85.3 mmHg, whereas it was 54.6 mmHg when iNO was successfully terminated. However, PaCO₂ was uncontrollable after ECMO in this case probably because of the medical history of obstructive lung disease. High plateau pressure more than 27cmH₂O is another risk, but it did not exceed throughout the treatment course. It is suggested that hypercapnia played some role in the development of ACP.

Pharmacological approach to treat ACP in ARDS patients is limited. It is reported that Levosimendan, a calcium synthesizer that has cardiogenic and phosphodiesterase III inhibitory effects, is useful for the treatment of PH [1], but it is not approved in Japan yet. Vasodilation effect of iNO could work in that condition, although iNO did not improve the mortality of ARDS [10]. If all other measures, independently or in combination, are not effective, iNO is a candidate as a rescue treatment in mechanically ventilated patients. In this case, we used iNO in combination with inotropic agents. RV pressure did not decrease after the start of iNO, but LV D-shape was attenuated. Furthermore, rapid decrease of iNO deteriorated RV function, whereas gradual reduction did not. These suggest that iNO played a role in treating ACP in this case. Recently, it is reported that iNO directly acts on COVID-19 virus, inhibits viral replication, reduces lung damage caused by inflammatory cells by suppressing neutrophil activation and subsequent cytokine release [5]. These direct effects of iNO on COVID-19 virus could

be a reason to introduce iNO against ACP.

5. Conclusion

ACP refractory to inotropic agents and ventilatory management in a COVID-19 associated ARDS patient could be treated by iNO. Our experience encourages to use iNO as a rescue measures to alleviate symptoms of ACP.

6. Acknowledgements

The authors acknowledge the assistance of Dr. Issei Tokimatsu, Department of Infectious Diseases, Showa University, and all of the clinical engineers and nurses for contributing 46-day long run of ECMO.

References

1. Zochios V, Parhar K, Tunnicliffe W, Roscoe A, Gao F. The Right Ventricle in ARDS. *Chest*. 2017; 152(1): 181-93.
2. Ackermann M, Verleden SE, Kuehnel M, Haverich A, Welte T, Laenger F, et al. Pulmonary Vascular Endothelialitis, Thrombosis, and Angiogenesis in Covid-19. *N Engl J Med*. 2020; 383(2): 120-8.
3. Vieillard-Baron A, Schmitt JM, Augarde R, Fellahi JL, Prin S, Page B, et al. Acute cor pulmonale in acute respiratory distress syndrome submitted to protective ventilation: incidence, clinical implications, and prognosis. *Crit Care Med*. 2001; 29(8): 1551-5.
4. Jeroen J, Bunge H, Caliskan K, Gommers D, Reis Miranda D. Right ventricular dysfunction during acute respiratory distress syndrome and veno-venous extracorporeal membrane oxygenation. *J Thorac Dis*. 2018; 10(Suppl 5): S674-82.
5. Kobayashi J, Murata I. Nitric oxide inhalation as an interventional rescue therapy for COVID-19-induced acute respiratory distress syndrome. *Ann Intensive Care*. 2020; 10(1): 61.
6. Vieillard-Baron A, Matthay M, Teboul JL, Bein T, Schultz M, Magder S, et al. Experts' opinion on management of hemodynamics in ARDS patients: focus on the effects of mechanical ventilation. *Intensive Care Med*. 2016; 42(5): 739-49.
7. Bein T, Grasso S, Moerer O, Quintel M, Guerin C, Deja M, et al. The standard of care of patients with ARDS: ventilatory settings and rescue therapies for refractory hypoxemia. *Intensive Care Med*. 2016; 42(5): 699-711.
8. Vieillard-Baron A, Price LC, Matthay MA. Acute cor pulmonale in ARDS. *Intensive Care Med*. 2013; 39(10): 1836-38.
9. Boissier F, Katsahian S, Razazi K, et al. Prevalence and prognosis of cor pulmonale during protective ventilation for acute respiratory distress syndrome. *Intensive Care Med*. 2013; 39(10): 1725-33.
10. Adhikari NK, Burns KE, Friedrich JO, Granton JT, Cook DJ, Meade MO. Effect of nitric oxide on oxygenation and mortality in acute lung injury: systematic review and meta- analysis. *British Medical J*. 2007; 334: 779.