

## A Case of Retroperitoneal Ectopic Pregnancy and Literature Review

Chi F<sup>1</sup>, Sun X<sup>2</sup>, Lv K<sup>2</sup>, Yu W<sup>2</sup> and Zhu Y<sup>2\*</sup>

<sup>1</sup>Department of Radiology, Qingdao Jiaozhou Central Hospital, Jiaozhou, 266300, China

<sup>2</sup>Department of Radiology, Qingdao Municipal Hospital, Qingdao, 266071, China

### \*Corresponding author:

Yueli Zhu,  
Department of Radiology, Qingdao Municipal Hospital,  
5 Donghaizhong Road, Qingdao 266071, Shandong  
Province, China, Tel: +8617663958098.  
E-mail: zhuyueli@aliyun.com

Received: 01 Sep 2021

Accepted: 16 Sep 2021

Published: 21 Sep 2021

### Copyright:

©2021 Zhu Y. This is an open access article distributed under the terms of the Creative Commons Attribution License, which permits unrestricted use, distribution, and build upon your work non-commercially.

### Citation:

Zhu Y, A Case of Retroperitoneal Ectopic Pregnancy and Literature Review. *Ann Clin Med Case Rep.* 2021; V7(9): 1-2

### Keywords:

Ectopic pregnancy; Retroperitoneal; CT

### 1. Abstract

Ectopic pregnancy is a rare female emergency that can have a serious impact on the patient and even threaten life. Retroperitoneal ectopic pregnancy as more rare ectopic pregnancy, its diagnosis and treatment are much more difficult. Here we provide a unique case of retroperitoneal ectopic pregnancy with multiple miscarriages, this may be important for the study of the mechanism of retroperitoneal ectopic pregnancy.

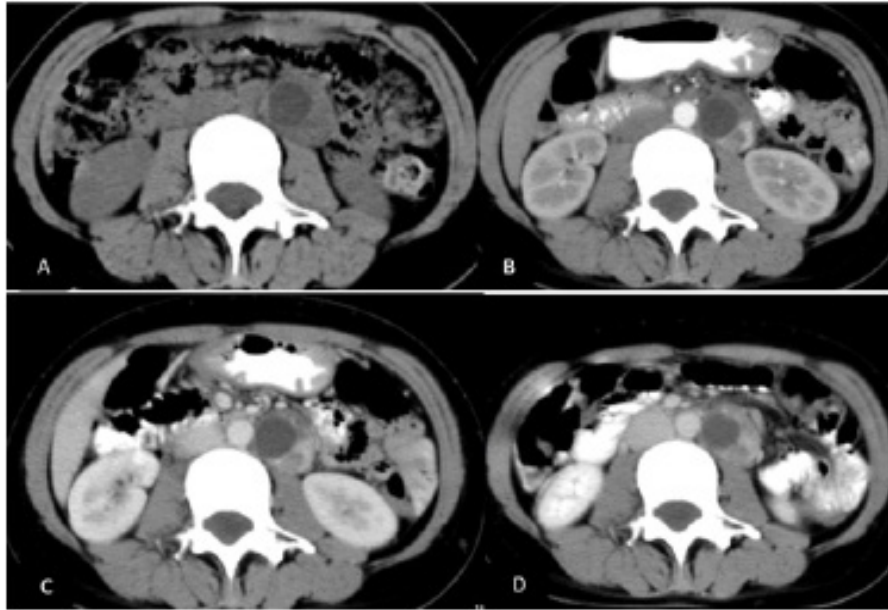
### 2. Introduction

Ectopic pregnancy is defined as the implantation of fertilized eggs into tissues outside the endometrium. Although the incidence of ectopic pregnancy has increased in the past few decades, the mortality caused by ectopic pregnancy has decreased due to the widespread use of high-resolution transvaginal ultrasound and laparoscopy [1]. It is important to note that retroperitoneal ectopic pregnancy as a very rare ectopic pregnancy, so far, the relevant studies are in the form of case reports, and no specific guidelines have been developed to manage the disease. Because the lesion is located near the retroperitoneal large blood vessel, surgical removal of pregnant tissue may cause vascular or nerve damage; on the other hand, the efficacy of conservative treatment with methotrexate is not ideal. Here, we report a case of retroperitoneal ectopic

pregnancy found by CT examination, hoping to increase clinical understanding and study of the disease.

### 3. Case report

A 39 years old female was admitted to our hospital because of blunt pain in the lower abdomen (G3P1, menopause for more than 2 month), no significant medical event was documented. Results of blood serum test showed that  $\beta$ -HCG:53175mIU/ml. progesterone 9.87ng/ml. Gynaecology ultrasound indicated no abnormal finding was detected. But computed-tomography(CT) scan revealed a type of round solid mass with 43HU(3.3 cm  $\times$ 4.2 cm in size) was found in the posterior peritoneal cavity. In contrast-enhancement CT, the CT value of arterial stage was 110HU, the CT value of portal stage was 102HU, the CT value of the delay period is 99HU (Figure 1). So, radiologists gave the consideration of retroperitoneal ectopic pregnancy. Open abdominal exploration was performed and there was a mass in the posterior peritoneal cavity, located next to the abdominal aorta. The inflammation around the mass was obvious, and the surgery was completed after blunt separation and complete excision of the mass and its surrounding inflammatory tissue. The mass tissue under light microscope was degeneration and necrotic chorionic cells and red blood cells. After 20 days of surgery,  $\beta$ -hCG decreased to 21.9 U/L.



**Figure 1a:** CT plain showing retroperitoneal aortic round cystic solid mass with a CT value of 43HU.

**Figure 1b,1c,1d:** After enhancement, the solid part is not uniformly strengthened, the CT value of arterial stage is 110HU, the CT value of portal vein stage is 102HU, and the CT value of delayed stage is 99HU.

#### 4. Discussion

Ectopic pregnancy accounts for about 2% of all pregnancies, and more than 95% of ectopic pregnancies occur in the fallopian tubes (also called fallopian tubes). But its pathogenesis is unclear. Known risk factors include reduced or impaired tubal transport activity, increased tubal receptivity in blastocyst implantation, tubal damage caused by surgery or infection, in vitro fertilization, and smoking [2, 3]. Regarding ectopic pregnancy, researchers have proposed four hypotheses: a) spontaneous retrograde migration of post-uterine embryos; b) iatrogenic placement of uterine perforated transfer embryos; c) transfuse implantation; d) transfer of embryos to the uterine cavity via a manner similar to lymphatic metastasis in endometrial cancer. retroperitoneal ectopic pregnancy is more rare, with three main pathogenesis pathways [4]: the embryonic lymphatic system reaches the retroperitoneal cavity; the retroperitoneal space is implanted through the fistula tract; embryo implantation first on the peritoneal surface, and then through the trophoblast infiltration through the peritoneum [5] to the retroperitoneal cavity. For the diagnostic criteria for retroperitoneal ectopic pregnancy, mainly: 1 menopause history, 2 sudden lumbar abdominal pain, but no trauma history, 3 vaginal bleeding, lower abdominal tenderness, but physical examination of moving turbidimetric (-), 4 serum hcg level elevation, 5 imaging examination showed that the mass was located in the retroperitoneum. However, because the location of retroperitoneal ectopic pregnancy is deep, and the surrounding anatomical structure is complex, so CT plays an important role in the diagnosis of suspected retroperitoneal ectopic pregnancy, this case is the final diagnosis through CT examination.

For retroperitoneal ectopic pregnancy, because of its low incidence, there is no specific treatment guide to manage the disease.

Because of the complex anatomical structure of retroperitoneum, the arteriovenous trunk travels through, the surgical removal of pregnancy tissue is easy to damage blood vessels, nerves and other tissues; in addition, methotrexate and other drugs used for conservative treatment of tubal ectopic pregnancy are not effective in the treatment of retroperitoneum ectopic pregnancy [6].

To sum up, we report a rare case of retroperitoneal ectopic pregnancy, because of the low incidence, easy to be misdiagnosed as acute abdomen and other common diseases, open surgery is also not easy to find ectopic pregnancy, so imaging examination, especially CT for the detection of this disease and the value of diagnosis should not be ignored.

#### References

1. A Martinez-Varea JJ, Hidalgo-Mora, V. Paya, I. Morcillo, E. Martin, A. Pellicer, Retroperitoneal ectopic pregnancy after intrauterine insemination, *Fertil.Steril.* 2011; 95: e2431-3.
2. Nio-Kobayashi J, Abidin HB, Brown JK, Iwanaga T, Horne AW, Duncan WC. Cigarette smoking alters sialylation in the fallopian tube of women, with implications for the pathogenesis of ectopic pregnancy. *Mol Reprod Dev.* 2016; 83: 1083-91.
3. Clark K, Baranyai J. Pelvic infection and the pathogenesis of tubal ectopic pregnancy. *Aust N Z J Obstet Gynaecol.* 1987; 27: 57-60.
4. Okorie CO. Retroperitoneal ectopic pregnancy: is there any place for non-surgical treatment with methotrexate? *J Obstet Gynaecol Res.* 2010; 36: 1133-6.
5. Plaus WJ. Retroperitoneal hemorrhage presenting as a ruptured ectopic pregnancy. *Ann Emerg Med.* 1987; 16: 1398-400.
6. H Iwama, S Tsutsumi, H Igarashi, K Takahashi, K Nakahara, H Kurachi. A case of retroperitoneal ectopic pregnancy following IVFET in a patient with previous bilateral salpingectomy. *Am J Perinatol.* 2008; 25: 33-6.