

## Acquired SAMD5-RET Fusion-Mediated Resistance to Gefitinib in Metastatic Non-Small Cell Lung Cancer Harboring EGFR-Activating Mutation: A Case Report

Dai S.<sup>1</sup>, Zhou P.<sup>3</sup>, Fenq M.<sup>2</sup> and Qiu Z.<sup>2\*</sup>

<sup>1</sup>Center of Gerontology and Geriatrics, West China Hospital, Sichuan University, Chengdu, P.R. China

<sup>2</sup>Department of Respiratory and Critical Care Medicine, West China Hospital, Sichuan University, Chengdu, P.R. China

<sup>3</sup>Department of Pathology, West China Hospital, Sichuan University, Chengdu, P.R. China

### \*Corresponding author:

Zhi Xin Qiu,  
Department of Respiratory and Critical Care  
Medicine, West China Hospital, Sichuan  
University, Chengdu, 610041, P.R. China.  
Tel: 86-2885423998,  
E-mail: qiuseagull@foxmail.com

Received: 13 Sep 2021

Accepted: 29 Sep 2021

Published: 04 Oct 2021

### Copyright:

©2021 Qiu Z. This is an open access article distributed under the terms of the Creative Commons Attribution License, which permits unrestricted use, distribution, and build upon your work non-commercially.

### Citation:

Qiu Z, Acquired SAMD5-RET Fusion-Mediated Resistance to Gefitinib in Metastatic Non-Small Cell Lung Cancer Harboring EGFR-Activating Mutation: A Case Report. *Ann Clin Med Case Rep.* 2021; V7(10): 1-7

### Authors' contributions:

Dai S, Zhou Pand Qiu Z, these authors are contributed equally to this article.

### Keywords:

lung cancer, EGFR; tyrosine kinase inhibitor, SAMD5-RET; resistance mechanism; case report

### Abbreviations:

CCDC6=coiled-coil domain containing 6; CT=computed tomography; EMT=endothelial-mesenchymal transition; EGFR=epidermal growth factor receptor; HER2 = human epidermal growth factor receptor-2; KIF5B = kinesin-1 heavy chain; MET = mesenchymal to epithelial transition factor; NGS = next generation sequencing; NSCLC = non-small cell lung cancer; NCOA4 = nuclear receptor coactivator 4; PIK3CA = phosphatidylinositol-4,5-bisphosphate 3-kinase catalytic subunit; RET=rearrangement during transfection; PD=progressive disease; SAMD5=sterile alpha motif domain containing 5; TKI=tyrosine kinase inhibitor; BRAF=v-raf murine viral oncogene homolog B1; TRIM24=tripartite motif containing 24; 19del=19 deletion

### 1. Abstract

**Background:** Patients with disease progression on first-generation tyrosine kinase inhibitors (TKIs) usually have a poor prognosis. The mechanisms of acquired resistance to epidermal growth factor receptor (EGFR)-TKI have been widely reported; however, reports of acquired rearrangement-during-transfection (RET) fusion are rare.

**Case Summary:** We report a case of lung adenocarcinoma with a novel sterile alpha motif domain containing 5 (SAMD5)-RET fusion as a mechanism of resistance to the first-generation EGFR-TKI, gefitinib. She was diagnosed with stage IVA (cT-3N2M1a) lung adenocarcinoma with metastases to the right lung

and right pleural cavity. Capture-based next generation sequencing (NGS) on pleural tumor sample revealed a molecular alteration in exon 19 deletion (19del) of EGFR. Gefitinib treatment was initi-

ated. Two months later, disease progression was confirmed, with enlargement of the lung tumor and increased pleural effusion, and NGS of tumor tissue revealed SAMD5-RET fusion with allelic frequency of 14.9%. Although the patient received the best supportive treatment, she died with an overall survival of 9 months.

**Conclusion:** This case extended the understanding of the mechanisms of acquired resistance to first-generation EGFR-TKIs. Re-biopsy and NGS may provide the basis for accurate treatment of advanced NSCLC.

## 2. Background

In non-small cell lung cancer (NSCLC), acquired epidermal growth factor receptor (*EGFR*) T790M mutation was found in almost 50%–60% of the EGFR-tyrosine kinase inhibitor (TKI) resistant cases [1], followed by human epidermal growth factor receptor-2 (*HER2*) amplification (8%–13%) [2], mesenchymal to

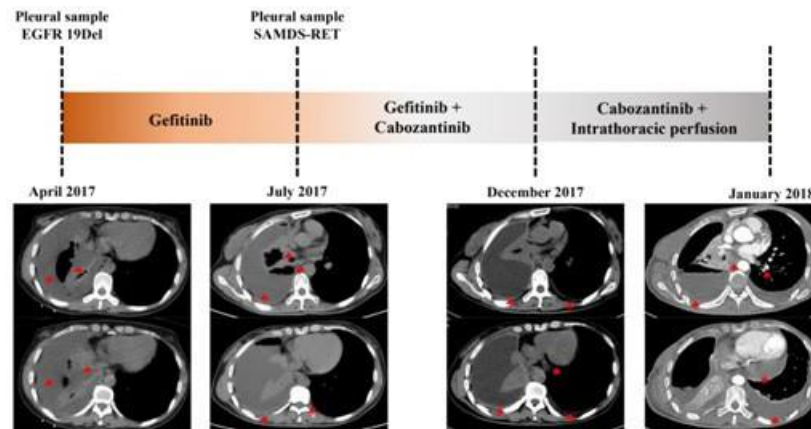
epithelial transition factor (*MET*) amplification (5%–10%) [3,4], small cell lung cancer (SCLC) transformation (5%) [5], endothelial-mesenchymal transition (EMT) (5%) [5], phosphatidylinositol-4,5-bisphosphate 3-kinase catalytic subunit (*PIK3CA*) mutation (1%–2%) [5] and v-raf murine viral oncogene homolog B1 (*BRAF*) mutation (1%) [6]. However, some of the resistance mechanisms are still unknown [7]. Here, we present the case of an *EGFR*-mutated non-small cell lung cancer (NSCLC) in a patient who developed a novel rearrangement-during-transfection (RET) fusion after progression on a first-generation *EGFR*-TKI.

### 3. Case Presentation

A 47-year-old never-smoker woman was admitted on April 20, 2017 due to right chest pain, cough and dyspnea. Right lung breath sounds decreased, percussion dullness. She was diagnosed with stage IVA (cT3N2M1a) lung adenocarcinoma with metastases to right lung and right pleura (Figure 1, 2). Capture-based next generation sequencing (NGS) on pleural tumor sample revealed a mo-

lecular alteration in exon 19 deletion (19Del) of *EGFR* (19exon p. E746\_A750del in-frame deletion mutation, c.2235\_2249del, p. Glu746\_Ala750del, allelic frequency: 63.08%). Subsequently, the patient was started on gefitinib 250mg once a day (QD) from May 2017. After two months of treatment, the patient's cough and dyspnea worsened. Disease progression was confirmed, with enlargement of the lung tumor and increased pleural effusion. (Figure 1).

Adenocarcinoma was confirmed in the rebiopsy specimen of the pleura, and NGS of tumor tissue revealed a sterile alpha motif domain containing 5 (*SAMD5*)-RET mutation with an allelic frequency of 14.9%, and the absence of the *EGFR* mutation (Figure 3). Therefore, the treatment regimen was changed to gefitinib 250mg QD + cabozantinib 80mg QD, and the symptoms of chest pain and dyspnea were alleviated. The patient progressed with a progression-free survival of 6 months in January 2018. Although the patient received the best supportive treatment, she died in April 2018 with an overall survival of 9 months.



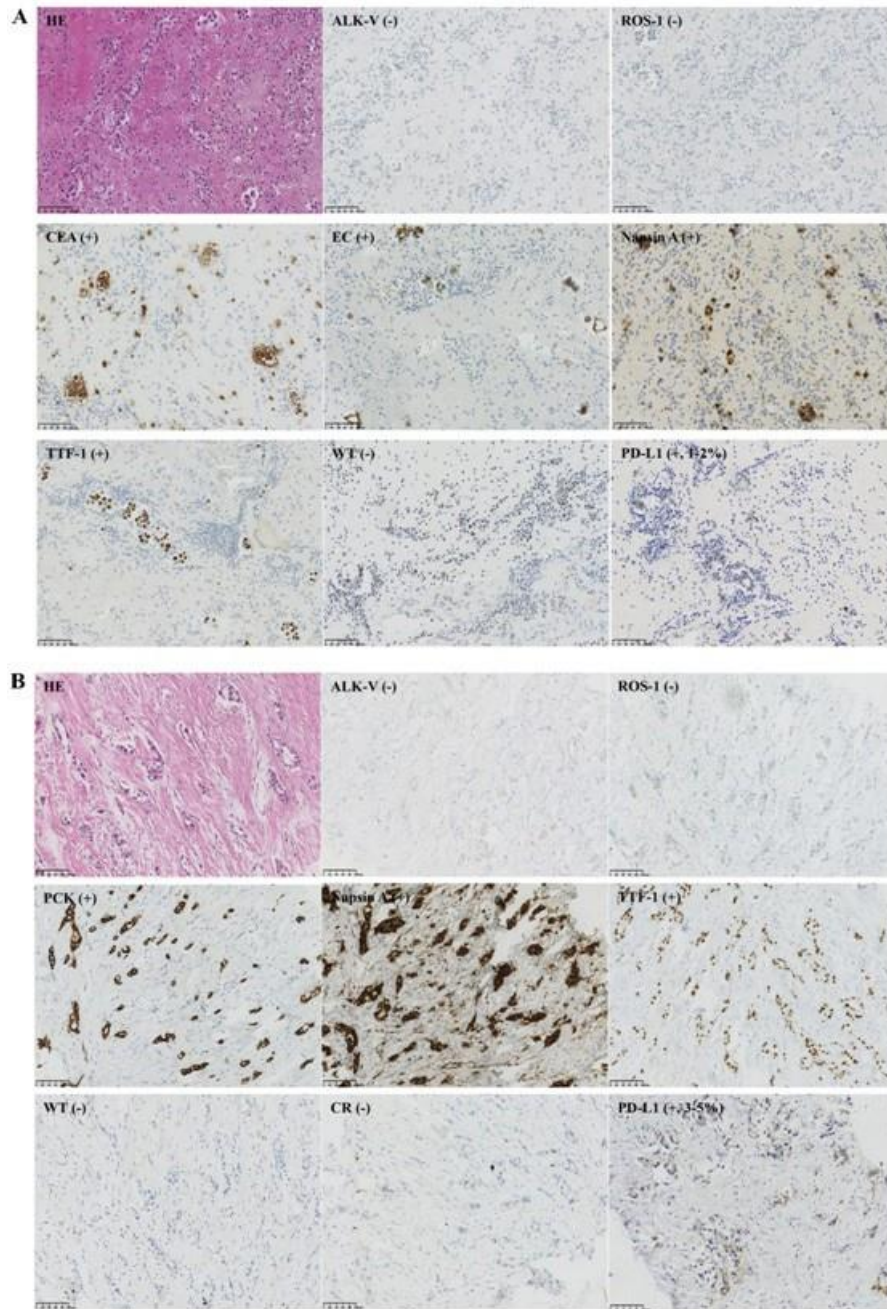
**Figure 1:** The main treatment processes and changes visualized on CT scans

Chest Computed tomography (CT) scan on April 22, 2017 showed irregular soft tissue shadow at the basal segment of the right lower lobe, enlarged mediastinal and right hilar lymph nodes, and right pleural effusion with pleural thickening.

Chest CT (July 11, 2017) showed massive pleural effusion in the right pleural cavity with extensive thickening of the right pleura, enlargement of the right hilar and mediastinal lymph nodes, and a small amount of pericardial effusion.

Chest CT (December 4, 2017) showed massive pleural effusion in the right pleural cavity with extensive thickening of the right pleura, and enlargement of the right hilar and mediastinal lymph nodes. The pericardium was thickened slightly with a small amount of pericardial effusion. In addition, a small thin nodular shadow under the left lung pleura and a small amount of pleural effusion on the left were observed.

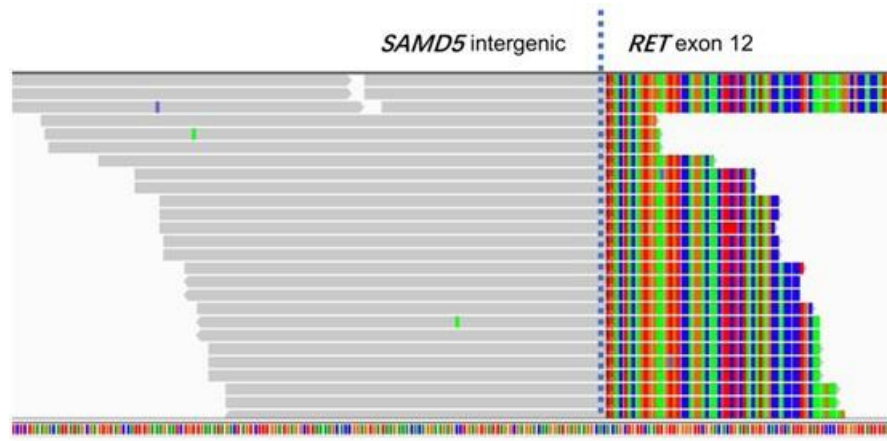
A pulmonary artery vasculature enhanced CT (January 16, 2018) indicated a low-density filling defect in the lumen of the pulmonary artery at the base of the left lower lobe basal segment, which suggested pulmonary thrombosis. Also, massive pericardial effusion and left pleural effusion could be observed.



**Figure 2:** Immunohistochemical images of pleural effusion and pleural tissue

**(A)** IHC results of the pleural effusion cell block were as follows: CEA(+), EC(+), Napsin A(+), TTF-1(+), WT-1(-), PD-L1(+, positive proportion about 1%-2%), ALK-V(-), ROS-1(-), which supported the diagnosis of lung adenocarcinoma.

**(B)** IHC results of pleural tissue were as follows: PCK(+), CK7(+), Napsin A(+), TTF-1(+), CR(-), WT-1(-), PD-L1(+, positive proportion about 3%-5%), ALK-V(-), ROS-1(-), which supported the diagnosis of lung adenocarcinoma.



**Figure3:** Thenovel gefitinib-resistant *RET* fusion mutation

**Supplementary Table 1.** Summary of acquired *RET* fusions in EGFR-TK resistant lung cancer patients.

A, Afatinib; E, Erlotinib; O, Osimertinib; G, Gefitinib; I, Icotinib; CZ, Crizotinib; CB, Cabozantinib; amp, Amplification; SD, Stable disease; PR, Partial response; Mo., month; Ref., Reference

No.	Author, year	EGFR mutation	EGFR TKI(s) before RET fusion	RET fusion	Other Mutations	Treatment after RET fusion	Response	Duration of response (Mo.)
				(mean allele frequency)				
1	Wang, 2020 <sup>12</sup>	L858R, T790M	O+ CZ	<i>CCDC6-RET</i>		O+ CB		Treatment ongoing
2	Klempner, 2015 <sup>21</sup>	19Del	E	<i>CCDC6-RET</i>				
3	Klempner, 2015 <sup>21</sup>	19Del	E	<i>CCDC6-RET</i>				
4	Piotrowska, 2018 <sup>15</sup>	19Del	A	<i>CCDC6-RET</i>	<i>TP53</i>	E + CB	SD	2.5
5	Piotrowska, 2018 <sup>15</sup>	19Del, T790M	A, O	<i>CCDC6-RET</i>		O+ BLU-667	PR	
6	Schrock, 2018 <sup>13</sup>	19Del (E746_A750del)	E	<i>CCDC6-RET</i>	<i>AKT2 amp, CCND3 amp, CCNE1 amp, BCL2L2 amp, NFKBIA amp, NKX2-1 amp, CDKN2A/B loss, TP53 Y205H, CBL Y371N, RAD51M1fs*8, SPAT1 R1077H</i>			
7	Schrock, 2018 <sup>13</sup>	19Del (E746_A750del)	E	<i>CCDC6-RET</i>	<i>AKT2 amp, CCND1 amp, AXL amp, CCNE1 amp, CDK6 amp, FGF19/3/4 amp, CDKN2A/B loss, PARK2 splice site, TP53 K120fs*26, PRMB1 K416fs*3, SMAD4 Y133fs*8</i>			
8	Schrock, 2018 <sup>13</sup>	19Del (E746_A750>IP)	E	<i>CCDC6-RET</i>				
9	Neal, 2016 <sup>19</sup>	NR	Gor E	<i>CCDC6-RET</i>				
10	Neal, 2016 <sup>19</sup>	NR	Gor E	<i>CCDC6-RET</i>				
11	Xu, 2019 <sup>11</sup>	L858R	O	<i>CCDC6-RET</i>	<i>EGFR amp</i>			
12	Oxnard, 2018 <sup>17</sup>	19Del, T790M	O	<i>CCDC6-RET</i>	<i>TP53 F270L</i>			
13	Xu, 2019 <sup>11</sup>	19Del (E746_T751del insA, T790M)	O	<i>CCDC6-RET</i>	<i>KRAS amp</i>	O		
14	Piotrowska, 2018 <sup>15</sup>	19Del, T790M	E, O	<i>CCDC6-RET</i>	<i>EGFR amp, BRAF amp, MET amp, CKD6 amp, CCNE1 amp, TP53, TERT, TPM3- NTRK1</i>			
15	Xu, 2019 <sup>11</sup>	19Del (E746_A750del, T790M)	O	<i>CCDC6-RET</i>		O		
16	Rich, 2019 <sup>14</sup>	19Del	E	<i>CCDC6-RET (0.1%)</i>	<i>EGFR T790M, EGFR T854A, EGFR amp, MET amp</i>	Pembrolizumab	SD	2
17	Rich, 2019 <sup>14</sup>	19Del, T790M	E, O	<i>CCDC6-RET (0.1%)</i>	NA			
18	Rich, 2019 <sup>14</sup>	19Del	U	<i>CCDC6-RET (0.1%)</i>	<i>EGFR T790M, EGFR amp</i>			
19	Rich, 2019 <sup>14</sup>	19Del, T790M	A, O	<i>CCDC6-RET (0.1%/0.4%)</i>		O+ bevacizumab; Chemotherapy	Progression; PR	10; Unknown

20	Rich, 2019 <sup>14</sup>	19Del,T790M	E,A, O, G	<i>CCDC6-RET</i> (0.2%)	<i>BRAFV600E,EGFRamp</i>			
21	Rich, 2019 <sup>14</sup>	19Del,T790M	O	<i>CCDC6-RET</i> (0.3%/0.2%/0.1%)				
22	Rich, 2019 <sup>14</sup>	19Del	Unknown	<i>CCDC6-RET</i> (0.5%)	<i>EGFR T790M,EGFR C797S, EGFR amp</i>			
23	Rich, 2019 <sup>14</sup>	19Del	E	<i>CCDC6-RET</i> (0.6%)	<i>EGFR T790M,EGFRamp, STRN-ALK</i> (0.2%)	O	Mixed response	3.5
24	Rich, 2019 <sup>14</sup>	L858R	E	<i>CCDC6-RET</i> (1.3%)	<i>EGFR T790M,EGFRamp, ERBB2 amp</i>			
25	Rich, 2019 <sup>14</sup>	19Del	E	<i>CCDC6-RET</i> (3.3%)	<i>EGFR G724S, EGFRamp, MET amp</i>			
26	Rich, 2019 <sup>14</sup>	19Del (E746_A750del, T790M, C797G/S)	O	<i>CDC123-RET</i>	<i>METamp</i>	O; Capmatinib		
27	Papadimitrakopoulou, 2018 <sup>16</sup>	19Del,T790M	O	<i>ERC1-RET</i>				
28	Zhu, 2019 <sup>9</sup>	19Del (L747_A750insP)	I	<i>KIF5B-RET</i>		I + CB	SD	2
29	Schrock, 2018 <sup>13</sup>	L858R	A	<i>NCOA4-RET</i>		A+ CB	SD	7
30	Piotrowska, 2018 <sup>15</sup>	19Del (L747_K754>G)	A+ cetuximab	<i>NCOA4-RET</i>	<i>RNF43, CDKN2A</i>	O+ BLU-667	PR	>12
31	Offin,2018 <sup>18</sup>	L858R,T790M	E,A, O	<i>NCOA4-RET</i>	<i>EGFR L747S</i>	O	Progression	
32	Xu, 2019 <sup>11</sup>	19Del (E746_A750del, T790M)	O	<i>NCOA4-RET</i>				
33	Le, 2018 <sup>20</sup>	19Del,T790M	O	<i>NCOA4-RET</i>	<i>JAK2V617F,MLH1E433Q, BRAFR735W,FGFR2E36K</i>			
34	Xu, 2019 <sup>11</sup>	19Del (L747_T751del, T790M)	O	<i>NCOA4-RET</i>				
35	Rich, 2019 <sup>14</sup>	19Del	Unknown	<i>NCOA4-RET</i> (0.2%)	<i>EGFR T790M,EGFR C797S, EGFR L792F,EGFRamp</i>			
36	Rich, 2019 <sup>14</sup>	L858R	E	<i>NCOA4-RET</i> (0.4%)				
37	Rich, 2019 <sup>14</sup>	19Del,T790M	E, O	<i>NCOA4-RET</i> (0.4%)	<i>EGFR C797S, EGFRamp</i>			
38	Rich, 2019 <sup>14</sup>	19Del	E	<i>NCOA4-RET</i> (1.3%)	<i>EGFRamp</i>			
39	Schrock, 2018 <sup>13</sup>	L858R	Unknown	<i>TRIM24-RET</i>				
40	Schrock, 2018 <sup>13</sup>	19Del (E746_A750del, T790M)	E, O	<i>TRIM24-RET</i>				
41	Rich, 2019 <sup>14</sup>	19Del	O	<i>TRIM24-RET</i> (4.7%)	<i>EGFRamp</i>			
42	Zhou, 2018 <sup>10</sup>	19Del or L858R, T790M	O	<i>RET</i>				

#### 4. Discussion

Our patient was diagnosed with lung adenocarcinoma and harbored the EGFR 19del mutation according to targeted sequencing on initial examination. The effect was poor and the disease progressed rapidly after treatment with gefitinib. Biopsy and targeted sequencing were repeated, and, interestingly, we found a novel SAMD5-RET fusion, and the original EGFR mutation was lost. We suspected whether the new mutation was induced following gefitinib treatment. Zhu et al. identified 86 receptor tyrosine kinase (RTK) fusions as acquired resistance mechanisms to EGFR TKIs in NSCLC from the literature, and RET fusions account for 43% of the RTK fusions [8]. Among the acquired RET fusion cases (Supplementary Table 1) [8-21], coiled-coil domain containing 6 (CCDC6)-RET (25/42, 59.5%) was the most common, followed by nuclear receptor coactivator 4 (NCOA4)-RET (10/42, 25.0%) and tripartite motif containing 24 (TRIM24)-RET (3/42, 7.1%). SAMD5-RET fusion has never been reported before. Most of the acquired fusions emerged after osimertinib treatment (21/42, 50.9%). Although cases with acquired RET mutation mediated resistance following gefitinib therapy are rare, further studies on the

mechanism are warranted.

However, even after administering gefitinib treatment combined with cabozantinib, the disease progressed rapidly, indicating that broad-spectrum antitumor drugs have a poor efficacy in patients with EGFR 19del mutation or RET fusion. Previous research found that 28% of patients with RET rearrangement experienced a partial response after treatment with cabozantinib [22]. Cabozantinib alone or in combination with erlotinib has superior efficacy to erlotinib alone in EGFR wild-type advanced lung cancer patients [19]. However, cabozantinib might have had no remarkable effect on our patient. Previous cases reported that patients with acquired RET fusion following treatment with erlotinib, icotinib, or afatinib combined with cabozantinib achieved stable disease (SD) for only 2–7 months [9, 13, 15]. However, a 69-year-old male with CCDC6-RET achieved partial response after receiving osimertinib plus cabozantinib [11]. Two patients achieved partial response (78%) after receiving BLU-667, a selective RET inhibitor [15]. Moreover, our previous research reported a female patient, harboring kinesin-1 heavy chain (KIF5B)-RET fusion with highly positive PD-L1 staining, who achieved a partial response for more than five



months after completion of immunotherapy [23]. These studies also provide real clinical data supporting our treatment of patients with RET fusion.

## 5. Conclusion

We reported a special case of acquired *RET* rearrangement in an *EGFR*-mutated NSCLC patient whose disease progressed on first-generation EGFR-TKI, gefitinib. This case indicates that rare new mutations may be induced during treatment with EGFR-TKIs, and that the *EGFR* mutation itself may be suppressed after treatment. In addition, patients with *RET* fusion may experience rapid disease progression and may be prone to pleural, lymph node, and distant metastases. Repeated biopsies and genetic tests are necessary for lung cancer patients with rapid disease progression during treatment.

## 6. Funding

This work was supported by the Central Government Guided Local Science and Technology Free Exploration Projects of Sichuan Province (2020ZYD005), the National Natural Science Foundation of China (81700095, 91859203, 81871890), the National Key Development Plan for Precision Medicine Research of China (2017YFC0910004), the National Major Science and Technology Project of China (2017ZX10103004-012) and the Major Science and Technology Innovation Project of Chengdu City (2020-YF08-00080-GX).

Department of Science and Technology of Sichuan Province (2021YFS0130)

## References

1. Kobayashi S, Boggon TJ, Dayaram T, Janne PA, Kocher O, Meyerson M, et al. EGFR mutation and resistance of non-small-cell lung cancer to gefitinib. *N Engl J Med*. 2005; 352(8): 786-792.
2. Takezawa K, Pirazzoli V, Arcila ME, Nebhan CA, Song X, Stanchina E, et al. HER2 amplification: a potential mechanism of acquired resistance to EGFR inhibition in EGFR-mutant lung cancers that lack the second-site EGFR T790M mutation. *Cancer Discov*. 2012; 2(10): 922-933.
3. Engelman JA, Zejnullahu K, Mitsudomi T, Song Y, Hyland C, Park JO, et al. MET amplification leads to gefitinib resistance in lung cancer by activating ERBB3 signaling. *Science*. 2007; 316(5827): 1039-1043.
4. Yu HA, Arcila ME, Rekhtman N, Sima CS, Zakowski MF, Pao W, et al. Analysis of tumor specimens at the time of acquired resistance to EGFR-TKI therapy in 155 patients with EGFR-mutant lung cancers. *Clin Cancer Res*. 2013; 19(8): 2240-2247.
5. Sequist LV, Waltman BA, Dias-Santagata D, Digumarthy S, Turke AB, Fidias P, et al. Genotypic and histologic evolution of lung cancers acquiring resistance to EGFR inhibitors. *Sci Transl Med*. 2011; 3(75): 75ra26.
6. Zhang Z, Lee JC, Lin L, Olivas V, Au V, LaFramboise T, et al. Activation of the AXL kinase causes resistance to EGFR-targeted therapy



inlungcancer.NatGenet.2012;44(8):852-860.

7. Wu SG, Shih JY. Management of acquired resistance to EGFR TKI-targeted therapy in advanced non-small cell lung cancer. *MolCancer*. 2018; 17(1): 38.
8. Zhu VW, Klempner SJ, Ou SI. Receptor Tyrosine Kinase Fusions as an Actionable Resistance Mechanism to EGFR TKIs in EGFR-Mutant Non-Small-Cell Lung Cancer. *Trends Cancer*. 2019; 5(11): 677-692.
9. Zhu YC, Wang WX, Zhang QX, Xu CW, Zhuang W, Du KQ, et al. The KIF5B-RET Fusion Gene Mutation as a Novel Mechanism of Acquired EGFR Tyrosine Kinase Inhibitor Resistance in Lung Adenocarcinoma. *Clin Lung Cancer*. 2019; 20(1): e73-e76.
10. Zhou C, Hu M, Zhu X, Sun Y, Wang J, Wang M, et al. Resistance Mechanisms of Osimertinib in Chinese Non-Small Cell Lung Cancer Patients: Analysis from AURA17 Trial. *Journal of Thoracic Oncology*. 2018; 13(10): S345-S345.
11. Xu H, Shen J, Xiang J, Li H, Li B, Zhang T, et al. Characterization of acquired receptor tyrosine-kinase fusions as mechanisms of resistance to EGFR tyrosine-kinase inhibitors. *Cancer Manag Res*. 2019; 11: 6343-6351.
12. Wang Y, Tian P, Xia L, Li L, Han R, Zhu M, et al. The clinical efficacy of combinatorial therapy of EGFR-TKI and crizotinib overcoming MET amplification-mediated resistance from prior EGFR-TKI therapy. *Lung Cancer*. 2020; 146: 165-173.
13. Schrock AB, Zhu VW, Hsieh WS, Madison R, Creelan B, Silberberg J, et al. Receptor Tyrosine Kinase Fusions and BRAF Kinase Fusions are Rare but Actionable Resistance Mechanisms to EGFR Tyrosine Kinase Inhibitors. *J Thorac Oncol*. 2018; 13(9): 1312-1323.
14. Rich TA, Reckamp KL, Chae YK, Doebele RC, Lams WT, Oh M, et al. Analysis of Cell-Free DNA from 32,989 Advanced Cancers Reveals Novel Co-occurring Activating RET Alterations and Oncogenic Signaling Pathway Aberrations. *Clin Cancer Res*. 2019; 25(19): 5832-5842.
15. Piotrowska Z, Isozaki H, Lennerz JK, Gainor JF, Lennes IT, Zhu VW, et al. Landscape of Acquired Resistance to Osimertinib in EGFR-Mutant NSCLC and Clinical Validation of Combined EGFR and RET Inhibition with Osimertinib and BLU-667 for Acquired RET Fusion. *Cancer Discov*. 2018; 8(12): 1529-1539.
16. Papadimitrakopoulou VA, Wu YL, Han JY, Barrett JC, Chmielec J, Ahn MJ, et al. Analysis of resistance mechanisms to osimertinib in patients with EGFR T790M advanced NSCLC from the AURA3 study. *Annals of Oncology*. 2018; 29: 741-741.
17. Oxnard GR, Hu YB, Mileham KF, Husain H, Costa D, Tracy P, et al. Assessment of Resistance Mechanisms and Clinical Implications in Patients With EGFR T790M-Positive Lung Cancer and Acquired Resistance to Osimertinib. *Jama Oncology*. 2018; 4(11): 1527-1534.
18. Offin M, Somwar R, Rekhtman N, Benayed R, Chang J, Plodkow-ski A, et al. Acquired ALK and RET Gene Fusions as Mechanisms of Resistance to Osimertinib in EGFR-Mutant Lung Cancers. *JCO Precis Oncol*. 2018; 2.
19. Neal JW, Dahlberg SE, Wakelee HA, Aisner SC, Bowden M, Huang Y, et al. Erlotinib, cabozantinib, or erlotinib plus cabozantinib as second-line or third-line treatment of patients with EGFR wild-type advanced non-small-cell lung cancer (ECOG-ACRIN 1512): a randomized, controlled, open-label, multicentre, phase 2 trial. *Lancet Oncol*. 2016; 17(12): 1661-1671.
20. Le X, Puri S, Negrao MV, et al. Landscape of EGFR-Dependent and -Independent Resistance Mechanisms to Osimertinib and Continuation Therapy Beyond Progression in EGFR-Mutant NSCLC. *Clinical Cancer Research*. 2018; 24(24): 6195-6203.
21. Klempner SJ, Bazhenova LA, Braithe FS, Nikolinakos PS, Gowen K, Cervantes C, et al. Emergence of RET rearrangement co-existing with activated EGFR mutation in EGFR-mutated NSCLC patients who had progressed on first- or second-generation EGFR TKI. *Lung Cancer*. 2015; 89(3): 357-359.
22. Drilon A, Rekhtman N, Arcila M, Wang L, Ni A, Albano M, et al. Cabozantinib in patients with advanced RET-rearranged non-small-cell lung cancer: an open-label, single-centre, phase 2, single-arm trial. *Lancet Oncol*. 2016; 17(12): 1653-1660.
23. Qiu Z, Ye B, Wang K, Zhou P, Zhao S, Li W, et al. Unique Genetic Characteristics and Clinical Prognosis of Female Patients with Lung Cancer Harboring RET Fusion Gene. *Sci Rep*. 2020; 10(1): 387.