

## After Sequential Therapy with First and Third Generation EGFR-Tkis, A Patient Acquired EGFR G719A Mutation and Responded to Afatinib, and Then, Acquired EGFR T790M Mutation When Developed Resistance to Afatinib: A Case Report

Yimin Wang<sup>a</sup>, Yong Song<sup>b\*</sup> and Hongbing Liu<sup>b\*</sup>

<sup>a</sup>Department of Respiratory Medicine, Jinling Hospital, Nanjing Medical University, Nanjing, China

<sup>b</sup>Department of Respiratory Medicine, Jinling Hospital, Nanjing University School of Medicine, Nanjing, China

### \*Corresponding author:

Yong Song,  
East Zhongshan Road 305, 211100 Nanjing, China;  
Tel:+86-25-80860049;  
E-mail: yongsong6310@yahoo.com and Hongbing Liu,  
Department of Respiratory and Critical Care Medicine,  
Affiliated Jinling Hospital, Medical School of Nanjing  
University, 305 East Zhongshan Road, Nanjing 210002,  
China. E-mail: netlhb@126.com

Received: 22 Mar 2022

Accepted: 08 Apr 2022

Published: 14 Apr 2022

J Short Name: ACMCR

### Copyright:

©2022 Yong Song, Hongbing Liu. This is an open access article distributed under the terms of the Creative Commons Attribution License, which permits unrestricted use, distribution, and build upon your work non-commercially.

### Citation:

Yong Song, Hongbing Liu, After Sequential Therapy with First and Third Generation EGFR-Tkis, A Patient Acquired EGFR G719A Mutation and Responded to Afatinib, and Then, Acquired EGFR T790M Mutation When Developed Resistance to Afatinib: A Case Report. *Ann Clin Med Case Rep.* 2022; V8(18): 1-4

### Keywords:

NSCLC; EGFR; Sequential therapy; EGFR G719A mutation; Case report

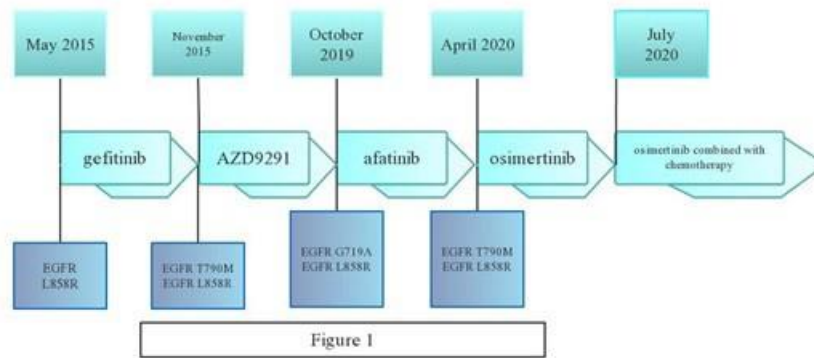
### 1. Abstract

NSCLC patients who had sensitive EGFR mutation had great possibility to get benefit from EGFR-TKIs. But this efficacy was relied on related EGFR mutation, if related EGFR mutation changed, resistance would happened. In our report, we did next generation sequencing(NGS) each time the patient had progression. We observed the patient acquired rare mutation after the resistance to third-generation EGFR-TKIs and this mutation was sensitive to second-generation EGFR-TKIs. And after the resistance to second-generation EGFR-TKIs, the patient had T790M EGFR mutation again and third-generation EGFR-TKIs could be continue taken.

### 2. Introduction

In Asia, about 50% of NSCLC patients will achieved EGFR mutation which is exquisitely responsive to EGFR-TKIs therapy [1-3].

Of all EGFR mutations, the EGFR exon 19 Del and EGFR L858R are accounted for about 84.6% [1-6]. However, despite the primary beneficial response, its always occurs resistance to the EGFR TKIs, most frequently by reason of the T790M mutation [7,8]. After patients acquired T790M mutation, third-generation TKIs like osimertinib can be used [9]. But the resistance to third-generation EGFR-TKIs always occurs, with a median time to progression of 10.1 months [10,11]. Thereafter, strategies for the administration of this condition have largely been limited to chemotherapy [12]. Besides, immune checkpoint inhibitor therapy and best supportive care are also recommended by standard guidelines [13]. With this background, we report an NSCLC patient who received sequential therapy with first, third, second generation EGFR-TKIs and finally returned to third generation EGFR-TKIs (Figure 1). Everytime we changed the patient's treatment, the accurate genetic test was utilized.

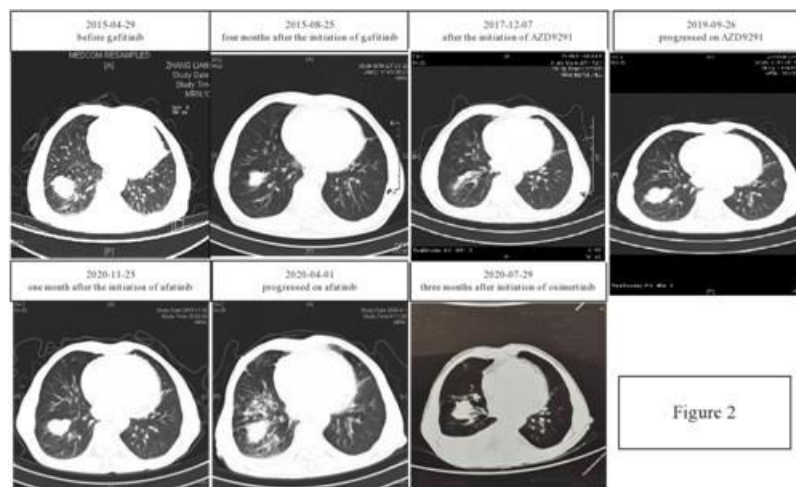


**Figure 1:** Diagram showing the treatment history of the patient.

**3. Case Report**

An 81-year-old male underwent computed tomography (CT) scans which showed a right lung upper lobe mass with intrapulmonary metastasis, multiple mediastinal lymph nodes enlarged and low density shadow of the left adrenal nodule in April 2015. Pathologic examination on CT-guided tissue biopsy (lung tissue) confirmed adenocarcinoma and molecular pathology of biopsy identified EGFR L858R mutation. The patient began taking gefitinib as first-line treatment. The computed tomography (CT) scans showed obvious shrinkage in the lesion, contributing to partial response. The partial response last about six months. Six months later, in November 2015, computed tomography (CT) scans emerged that the lesion was progressed and AZD9291 was taken as second-line treatment when EGFR T790M was detected by next generation sequencing(NGS). After the application of AZD9291, computed tomography (CT) scans showed the lesion consistent disease control. And the patient continued on AZD9291 treatment last about three years. Then, in September 2019, the computed tomography (CT) scans revealed enlarged lesion. One month later, in

October 2019, the patient required hospitalization for encephalalgia, dizziness and unsteady walking. The patient also complained that his right extremities were numb and weak. Subsequent next generation sequencing(NGS) of tissue biopsy at the time of relapse confirmed an acquired EGFR G719A mutation in addition to the original EGFR L858R mutation. According to the result of next generation sequencing(NGS), the patient commenced on afatinib as the third-line treatment. Then, his clinical symptoms were notably relieved and radiograph revealed with reduced lesion. However, on May 31, 2020, the patient got worsen cough and coughed up a lot of white sputum. The Computed tomography (CT) scans in April 2020 demonstrated worsening of the lesion. Repeated next generation sequencing(NGS) detected the emergence of EGFR T790M mutation, in conjunction with EGFR L858R mutation (Table 1). Therefore the patient achieved osimertinib as the fourth line treatment. Finally, in August 2020, the patient got worsen cough and suffered from headache. the computed tomography (CT) scans revealed enlarged lesion (Figure 2). He went to another hospital and was treated with osimertinib combined with chemotherapy. Until now the cut off day, the patient still alive.



**Figure 2:** Computed tomography (CT) scans are ordered according to the time point relative to the treatment.

2015-05				2015-11			
Gene	Exon	Amino acid change		Gene	Exon	Amino acid change	
EGFR	21	L858R		EGFR	21	L858R	
					20	T790M	
2019-10				2020-04			
Gene	Exon	Amino acid change	Enrichment	Gene	Exon	Amino acid change	Enrichment
EGFR	21	L858R	3.27%	EGFR	21	L858R	0.49%
	18	G719A	8.61%		20	T790M	0.35%

**Table 1:** Next generation sequencing(NGS) screenshot in 2015-05 revealed EGFR L858R mutation. Next generation sequencing(NGS) screenshot in 2015-11 revealed the original EGFR L858R mutation in addition to an acquired EGFR T790M mutation. Next generation sequencing(NGS) screenshot in 2019-10 revealed the original EGFR L858R mutation in addition to an acquired EGFR G719A mutation. Next generation sequencing(NGS) screenshot in 2020-04 revealed EGFR L858R mutation and EGFR T790M mutation.

#### 4. Discussion

Resistance mutation would be acquired in patients with EGFR-TKIs resistance in some percentage [14] But some of these mutations were rare to see. The occurrence of EGFR G719X mutation after third generation EGFR-TKIs resistance ranged between 2% and 5% [15]. Here we describe an unreported case. Each time the disease progressed, the patient acquired resistance mutation and got clinical benefit from the sequential therapy with first, third, second and third generation EGFR-TKIs. The patient was treated by first generation EGFR-TKIs after the detection of the EGFR 21 exon L858R mutation. And he changed the treatment to the third generation EGFR-TKIs when he was detected with EGFR L858R mutation and EGFR T790M mutation after resistance. After the resistance to third generation EGFR-TKIs, repeated next generation sequencing(NGS) revealed he acquired EGFR G719A mutation, besides the original EGFR L858R mutation and treated with the second generation EGFR-TKIs. Finally, the patient received next generation sequencing(NGS) again, after the resistance to second generation EGFR-TKIs, he was detected with EGFR L858R mutation and EGFR T790M mutation and treated with third generation EGFR-TKIs continued.

During the treatment, accurate genetic tests had been utilized. Every time, when the patient developed the resistance to the EGFR-TKIs, he achieved next generation sequencing(NGS). And according to the outcomes, we adjusted his treatment. Based on the accurate genetic tests, our selections of therapeutic schedule will have more scientific evidence and will be more targeted. As we reported, the patient had durable clinical response. The patient was diagnosed with a stage IV adenocarcinoma of the lung in May 2015 and treated with EGFR-TKIs. His treatment was adjusted under the guidance of next generation sequencing(NGS) and now, in the end of 2020, the patient still alive.

#### 5. Conclusion

Our report provides a rare case of sequential therapy with EGFR-TKIs. A rare mutation (EGFR G719A) occurred after osimertinib resistance and the second generation EGFR-TKIs can be used. By coincidence, EGFR T790M mutation acquired again and osimertinib can be used again. These mutations prolonged sequential therapy. In similar conditions, our treatment therapy can be an option. Furthermore, our report also highlights the significance of accurate genetic tests in the treatment progress and confirmed that accurate genetic tests can guide our options of treatment.

#### References

- Peng M, Wen Q, Wu X. Osimertinib for compound EGFR exon 19 deletion/T790M mutated lung squamous cell carcinoma [J]. *Thorac Cancer*, 2020; 11(9): 2704-2708.
- Hirsch F R, Vignani P J. EGFR testing in lung cancer is ready for prime time[J]. *Lancet Oncol*. 2009; 10(5): 432-433.
- Castellanos E, Feld E, Horn L. Driven by Mutations: The Predictive Value of Mutation Subtype in EGFR-Mutated Non-Small Cell Lung Cancer[J]. *J Thorac Oncol*. 2017; 12(4): 612-623.
- Mok T S, Wu Y L, Thongprasert S. Gefitinib or carboplatin-paclitaxel in pulmonary adenocarcinoma[J]. *N Engl J Med*. 2009; 361(10): 947-957.
- Maemondo M, Inoue A, Kobayashi K. Gefitinib or chemotherapy for non-small-cell lung cancer with mutated EGFR[J]. *N Engl J Med*. 2010; 362(25): 2380-2388.
- Wu Y L, Zhou C, Hu C P. Afatinib versus cisplatin plus gemcitabine for first-line treatment of Asian patients with advanced non-small-cell lung cancer harbouring EGFR mutations (LUX-Lung 6): an open-label, randomised phase 3 trial[J]. *Lancet Oncol*. 2014; 15(2): 213-222.
- Minari R, Bordi P, Tiseo M. Third-generation epidermal growth factor receptor-tyrosine kinase inhibitors in T790M-positive non-small cell lung cancer: review on emerged mechanisms of resistance[J]. *Transl Lung Cancer Res*. 2016; 5(6): 695-708.

8. Suda K, Onozato R, Yatabe Y. EGFR T790M mutation: a double role in lung cancer cell survival?[J]. *J Thorac Oncol*. 2009; 4(1): 1-4.
9. Jänne P A, Yang J C, Kim D W. AZD9291 in EGFR inhibitor-resistant non-small-cell lung cancer[J]. *N Engl J Med*. 2015; 372(18): 1689-1699.
10. Leonetti A, Sharma S, Minari R. Resistance mechanisms to osimertinib in EGFR-mutated non-small cell lung cancer[J]. *British Journal of Cancer*. 2019; 121(9): 725-737.
11. Oxnard G R, Hu Y, Mileham K F. Assessment of Resistance Mechanisms and Clinical Implications in Patients with EGFR T790M-Positive Lung Cancer and Acquired Resistance to Osimertinib[J]. *JAMA Oncol*. 2018; 4(11): 1527-1534.
12. Arulananda S, Do H, Musafar A. Combination Osimertinib and Gefitinib in C797S and T790M EGFR-Mutated Non-Small Cell Lung Cancer[J]. *J Thorac Oncol*. 2017; 12(11): 1728-1732.
13. Ettinger D S, Wood D E, Aggarwal C. NCCN Guidelines Insights: Non-Small Cell Lung Cancer, Version 1.2020[J]. *J Natl Compr Canc Netw*. 2019; 17(12): 1464-1472.
14. Harrison P T, Vyse S, Huang P H. Rare epidermal growth factor receptor (EGFR) mutations in non-small cell lung cancer[J]. *Semin Cancer Biol*. 2020; 61: 167-179.
15. Floc'H N, Lim S, Bickerton S. Osimertinib, an Irreversible Next-Generation EGFR Tyrosine Kinase Inhibitor, Exerts Antitumor Activity in Various Preclinical NSCLC Models Harboring the Uncommon EGFR Mutations G719X or L861Q or S768I[J]. *Mol Cancer Ther*. 2020.
- 16.16.