

Vonlay; A Paradigm Shift in Post Endodontic Restoration: A Case Report

Mookhtiar H*, Hegde V, Shanmugasundaram S, Memon Z and Malik AZ

Department of Conservative dentistry and Endodontics, MARangoonwala dental college and research centre, India

*Corresponding author:

Hussain Mookhtiar,
Department of Conservative dentistry and
Endodontics, MARangoonwala dental college and
research centre, Pune, India, Tel: +919930951615; E-
mail:- drhussainmookhtiar93@gmail.com

Received: 08 Jul 2022

Accepted: 16 Jul 2022

Published: 22 Jul 2022

J Short Name: ACMCR

Copyright:

©2022 Mookhtiar H. This is an open access article distributed under the terms of the Creative Commons Attribution License, which permits unrestricted use, distribution, and build upon your work non-commercially

Keywords:

Vonlay; Onlay; Veneer; Premolars; Postendodontic restoration

Citation:

Mookhtiar H, Vonlay; A Paradigm Shift in Post Endodontic Restoration: A Case Report. Ann Clin Med Case Rep. 2022; V9(11): 1-4

1. Abstract

Porcelain veneers have long been a popular restorative option that have evolved into a well-accepted treatment that can be fabricated in various ways. Onlays are another common treatment modality used in contemporary dentistry to restore large areas of decay and to replace old restorations. With the availability of newer high-strength materials such as lithium disilicate and processing technologies like CAD/CAM and heat pressing, dental professionals are now able to produce highly esthetic, high-strength restorations that blend seamlessly with the natural dentition while also withstanding posterior occlusal forces. A tooth more complex restoration is required after endodontic treatment when compared to normal tooth restoration, because of factors such as extensive caries, post-treatment root canal dentin and even the economic condition of the patient. One such design proposed by Dr. Ronald E Goldstein is "Veenerlay" or "Vonlay". Vonlay is a blend of an onlay with an extended buccal veneer surface for use in premolar region, where there is sufficient enamel present to bond. This restorative option requires a much less invasive preparation than a full coverage crown but provides the same structural benefits. Thus, the aim of this case report is to present a case of Vonlay following endodontic treatment of lower mandibular premolar

2. Introduction

Preserving tooth structure is critical for the longevity of teeth and restorations. It is obviously an advantage to save the pulp vitality and delay the need for endodontic treatment, dowels, and cores,

because these are more invasive treatments that adversely affect the performance of restored teeth over time [1].

With the availability of newer high-strength materials like lithium disilicate ceramic along with the processing technologies like CAD/CAM and heat pressing, dental professionals are now able to offer their patients highly esthetic, high-strength restorations that not only blend seamlessly with the existing dentition, but also withstand occlusal forces even in thin sections [2].

In contemporary restorative dentistry, there are several ways for clinicians to enhance the shape, color, or position of teeth, and, moreover, various materials and processing methods are available to fabricate restorations.

One such design proposed by Dr. Ronald E Goldstein is "Veenerlay" or "Vonlay". Vonlay is a blend of an onlay with an extended buccal veneer surface for use in premolar region, where there is sufficient enamel present to bond. This restorative option requires a much less invasive preparation than a full coverage crown but provides the same structural benefits.

Simultaneously, with the components of an onlay and veneer-vonlay enhances the durability and esthetics of the preserved tooth structure [3, 4].

The purpose of the present paper is to present a clinical case, in which an esthetic and conservative posterior Vonlays are used to restore multi-rooted teeth that presented endodontic treatment and extensive coronal destruction.

3. Case Report

A 26-year-old female was referred to the Department of Conservative Dentistry and Endodontics at M.A.Rangoonwala College of Dental Sciences and Research Centre, Pune. She suffered from deep occlusal carious lesions suspected of pulpal involvement. After through radiographic and clinical examinations to check the amount of remaining tooth structure and confirmation of pulpal involvement, non-surgical endodontic treatment was proposed to the patient and performed. For Postendodontic treatment planning after patient's oral hygiene considerations was acceptable and a favourable occlusion and aesthetic consideration vonlay restoration fabricated from monolithic lithium disilicate (IPSe.max) was proposed as an alternative to full crown which was agreed by the patient. Prior to commencement of preparation, shade selection was done (Figure 1 and 2).

Occlusal Preparation (Onlay)

The aim was to achieve overall reductions in the height of the occlusal surfaces of at least 2mm in the axial direction and to get a Occlusal table or "Occlusal sidewalk" in the form of a butt joint. Occlusal Preparations were done using a flat ended tapered diamond bur to achieve a shoulder finish line for the seating of the ceramic onlay.

Buccal Preparation (Veneer)

Depth cuts were placed on the buccal surface using diamond depth cutting bur. The remaining enamel was removed using round end tapered diamond bur to obtain a supragingival chamfer finish line which will aid in placement of the veneer. Proximal reduction was performed using round end tapered diamond bur parallel to the long axis of the tooth. The proximal reduction was stopped just short of breaking the contact. The final finishing of the preparation was done using fine grit diamond bur (Figure 3, 4 and 5).

After the completion of tooth preparation impression was made with polyvinylsiloxane impression material of light and putty consistency using a double-mix single-stage technique. The Lithium Disilicate was milled using CAD/CAM milling technique (Figure 6).

After verifying the fit, the vonlay was cemented intraorally using resin luting cement. The inner surface was etched with 10% hydro-fluoric acid was washed with water and dried.

Silane coupling agent was applied for 1 min and dried. The tooth was etched for 10 seconds and washed and dried using botting paper. Adhesive was applied and cured for 20 secs. Resin cement was applied on the inner surface and vonlay was cemented using light cure. The gross occlusal discrepancies were marked with articulating paper strips and later removed before cementation (Figure 7 and 8).

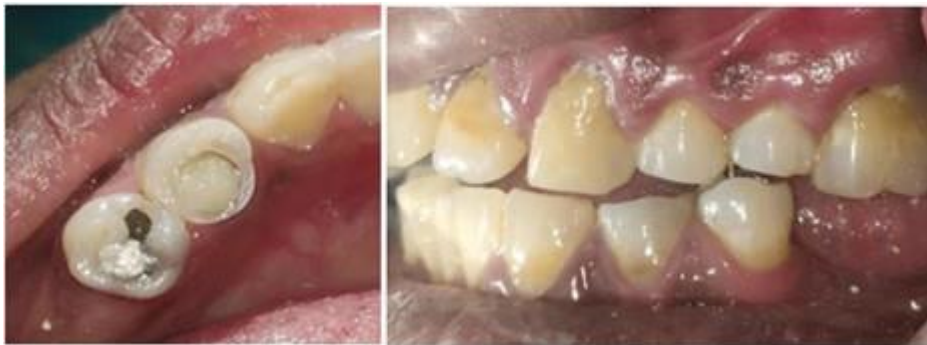

Figure 1 and 2: Pre-operative

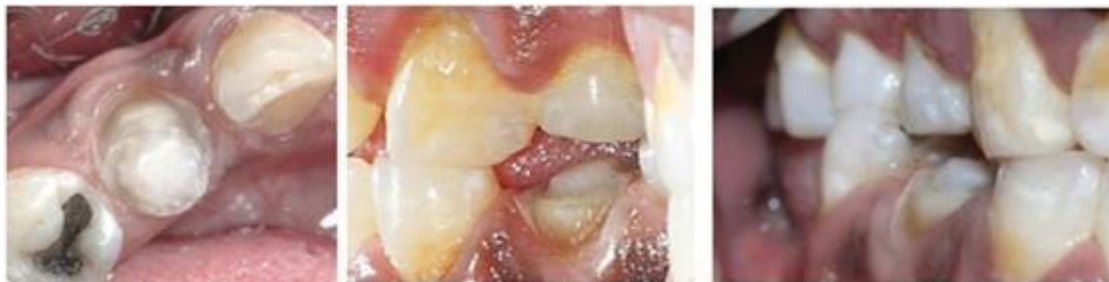

Figure 3, 4 and 5: Final tooth preparation

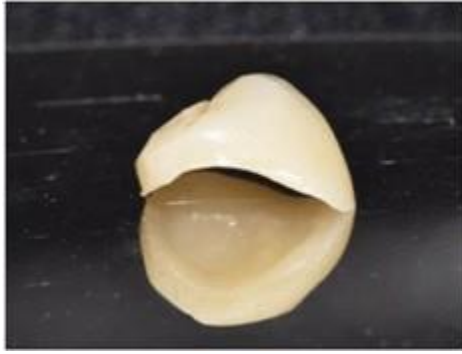


Figure 6: CAD/CAM milled Vonlay

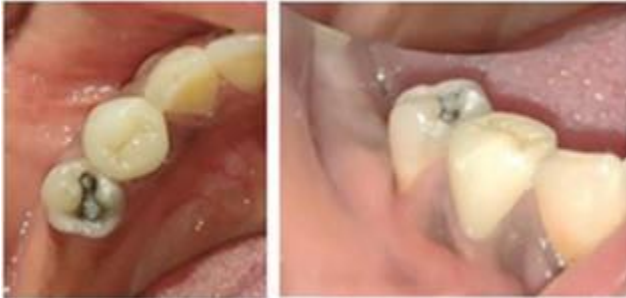

Figure 7 and 8: Postcementation

4. Discussion

There are two broad categories of fixed dental prosthesis; old category known as conventional restorations that depend on frictional or mechanical retention and recent category known as minimally invasive MI or adhesive restorations that depend on adhesives [5]. Conventional restorations can be fabricated from esthetic or non-esthetic materials whereas MI restorations are fabricated from esthetic material only. Nowadays, selecting the best restorative option for posterior teeth is a challenge because of many minimally invasive restorations available [6].

Traditionally, if a patient requires restoration in the posterior region, full coverage restoration was thought to be the ideal treatment option, however the problem encountered with the full coverage restoration which includes increasing the amount of tooth reduction which may lead in some cases to pulp involvement resulted in a shift to recently introduced minimally invasive dentistry which aims to preserve as much tooth structure as possible whenever feasible [7]. So, Partial coverage restorations have been introduced in the dental field trying to fulfill the idea of conservative preparation where minimal preparation of the teeth is done, thus enhancing mechanical resistance and retention forms [8].

The rationale behind Ceramic onlays, Endocrowns, Vonlays and Crownlays is that a monolithic ceramic bonded restoration with a butt joint keeping as much as possible enamel for improved adhesion and aesthetics [9].

One of the newly introduced approaches is the Vonlay that are considered a conservative combination approach combining the veneer and the onlay restorations and can be used as an alternative to full coverage restoration in the posterior region. It covers the

buccal and occlusal surfaces of the teeth. The buccal surface is covered by veneer which can fulfill the aesthetic considerations as well as partial coverage restoration. Veneers are rarely given for premolar restoration [10].

Ceramic veneers can be computer-assisted design/computer-assisted manufacture (CAD/CAM)-milled and sintered from blocks, or heat-pressed from ingots. Milled veneers are generally indicated for areas where lower occlusal forces are expected, because they are weaker than their pressed counterparts (approximately 360 MPa for milled restorations versus 400 MPa for pressed restorations). However, the pressed restorations can be used even in the posterior region [11].

Onlays are also used to replace old restorations, whether they are defective amalgam fillings, old cast-gold onlays, porcelain fused to metal (PFM), or fabricated from some other material. As with veneers, the aggressiveness of the preparation design depends largely on the severity of the damage to the tooth being restored [12].

Ceramic onlays may be CAD/CAM-milled or heat pressed. Like other all-ceramic restorations, they have seen a dramatic improvement during the years of their clinical use due to material science improvements. Ceramics formulated with feldspathic porcelain, mica-filled glass, leucite-reinforced ceramics, or lithium disilicate are all used in today's metal-free restorations with high success rates. The improved ceramics in onlay restorations allow conservative preparation design similar to those that can be achieved with other materials and restorations. These ceramics produce restorations that are highly translucent—and, therefore, highly esthetic—and that have excellent marginal integrity and enhanced proximal contacts, demonstrate minimal wear, and do not fracture or abrade opposing teeth [3, 13].

Vonlays or veneerlays veneer on buccal surface + onlay, a restoration covering the occlusal and palatal surfaces may be called reversed vonlay and so on. This will open the door to many new names of restorations and more controversy and confusion [14].

According to a study conducted by Nadig RR et al inferred that stress seen with indirect onlay, Vonlay as post endodontic restorative designs were relatively less and can be regarded as suitable alternative to full crown restorations for restoring ETT maxillary premolar [13]. Also, Elsayed concluded that statistically significant difference was found between IPS e.max and VITA Suprinity where the highest mean value was recorded in VITA Suprinity group [11].

Oguz reported a case of severely worn dentition with Partial Lithium Disilicate Glass Ceramic Restorations using Vonlay [12].

5. Conclusion

Vonlays represents a very hopeful treatment alternative for endodontically treated premolars, it allows maintaining of tooth structure, it is compatible with minimally invasive dentistry, and it is adequate for the concept of biointegration. It is a conservative ap-

proach for mechanical and aesthetic restoration of nonvital posterior teeth.

References

1. Larson TD. 25 years of veneering: what have we learned? *Northwest Dent.* 2003; 82(4): 35-9.
2. Heffernan MJ, Aquilino SA, Diaz-Arnold AM, et al. Relative translucency of six all-ceramic systems. Part I: core materials. *J Prosthet Dent.* 2002; 88(1): 4-9.
3. McLaren EA, Figueira J, Goldstein RE. Vonlays: a conservative aesthetic alternative to full-coverage crowns. *Compend Contin Educ Dent.* 2015; 36(4): 282, 284, 286-9.
4. Rocca GT, Bonnafous F, Rizcalla N, Krejci I. A technique to improve the esthetic aspects of CAD/CAM composite resin restorations. *J Prosthet Dent.* 2010; 104: 273-5.
5. Lin CL, Chang YH, Pa CA. Estimation of the risk of failure for an endodontically treated maxillary premolar with MODP preparation and CAD/CAM ceramic restorations. *J Endod.* 2009; 35: 1391-5
6. Elsaka SE, Elnaghy AM. Mechanical properties of zirconia reinforced lithium silicate glass-ceramic. *Dental Materials.* 2016; 32(7): 908-14
7. Yoshida T, Kurosaki Y, Mine A, Kimura-ono A, Mino T, Osaka S et al. Fifteen-year survival of resin-bonded vs full-coverage fixed dental prostheses. *Journal of Prosthodontic Research.* 2019; 63(3): 374-82.
8. Jiang W, Bo H, Yongchun G, Longxing N. Stress distribution in molars restored with inlays or onlays with or without endodontic treatment: A three-dimensional finite element analysis. *J Prosthet Dent.* 2010; 103(1): 6-12
9. Bergmann CP, Stumpf A. Dental ceramics: Microstructure, properties and degradation. In *Dental Ceramics: Microstructure, Properties and Degradation.* Springer Berlin Heidelberg. 2013.
10. Mainjot AKJ. The One step-No prep technique: A straightforward and minimally invasive approach for full-mouth rehabilitation of worn dentition using polymer-infiltrated ceramic network (PICN) CAD-CAM prostheses. *J Esthet Restor Dent.* 2020; 32(2): 141-9.
11. Elsayed M, Sherif R, El-khodary N. Fracture resistance of Vita supriminity versus IPS e.max CAD vonlays restoring premolars (An in vitro study). *Int J Appl Dent Sci.* 2020.
12. Oğuz Eİ, Berksun S. Rehabilitation of a Severely Worn Dentition with Partial Lithium-Disilicate Glass Ceramic Restorations: A Case Report. *European Annals of Dental Sciences.* 2021; 48(1): 28-32.
13. Nadig RR, Garian R. Stress distribution pattern in endodontically treated mesio occlusally involved premolars restored with ceramic onlay, vonlay and full crown restorations.
14. Sultan S, Al Garni H, Al Onazi M, Gangi KK, Al Otha S, Al Ruwaili F, et al. Minimally Invasive Posterior Full Crown Competitors: Onlays, Occlusal Veneers, Vonlays and Endocrowns: A Review and Proposed Classification. *Journal of International Dental and Medical Research.* 2021; 14(4): 1617-22.