

# Massive Upper Gastrointestinal Bleeding Unveils A Large Jejunal GIST: Case Report And Literature Insights

Harsha Narayan\*, Vikrant Singh Chauhan and Avinash Koul

Department of General Surgery, Minimal Access, Bariatric and Robotic Surgery, Fortis Hospital, Noida, U.P., India

\*Corresponding author:

Harsha Narayan,

Department of General Surgery, Minimal Access Surgery, Bariatric and Robotic Surgery, Fortis Hospital, Noida (U.P.), India. Orchid id - 0009-0002-5859-6962

**Received Date:** 09 Aug 2024

**Accepted Date:** 21 Aug 2024

**Published Date:** 26 Aug 2024

## Citation:

Harsha Narayan. Massive Upper Gastrointestinal Bleeding Unveils A Large Jejunal GIST: Case Report And Literature Insights. Annals of Clinical and Medical Case Reports 2024.

## 1. Abstract

**1.1. Introduction:** Gastrointestinal stromal tumors (GISTs) are rare tumors of the digestive tract, most commonly found in the stomach, with jejunal GISTs being particularly uncommon. Diagnosis is often challenging due to non-specific clinical and radiological findings. We present a case of a jejunal GIST diagnosed through histopathology, following non-specific symptoms.

**1.2. Case presentation:** A 65-year-old man with a history of diabetes and hypertension presented to the emergency department with a three-day history of bowel obstruction, along with one day of hematemesis and melena. Physical examination revealed a tender mass in the epigastrium extending to the umbilicus. A contrast-enhanced CT scan of the abdomen showed a large exophytic mass originating from the jejunum. The patient was transferred to intensive care, resuscitated, and underwent emergency laparotomy with resection and anastomosis of the jejunal mass. Histopathology confirmed the diagnosis of jejunal GIST. The patient recovered well postoperatively and was discharged on imatinib therapy, with no complications or metastasis at six months follow-up.

**1.3. Discussion:** GISTs can present atypically, with massive bleeding being potentially life-threatening, necessitating prompt treatment. Due to the lack of specific clinical or imaging signs, histopathology and immunohistochemistry become essential, making Jejunal GISTs a rare diagnosis.

**1.4. Conclusion:** It is important to understand the inconspicuous presentation of GISTs and keep a high degree of suspicion in elderly patients presenting with gastrointestinal bleeding and an acute abdomen, the treatment of which does not stop at surgery.

## 2. Keywords:

Case report, GIST, Gastrointestinal bleeding, Jejunal tumor

## 3. Introduction

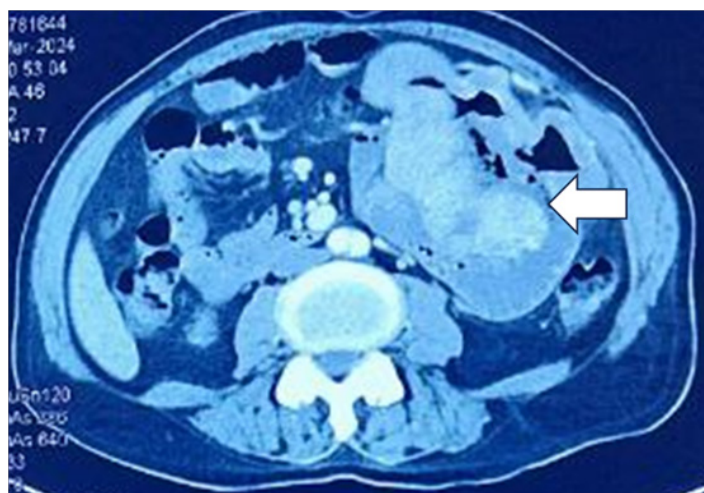
Gastrointestinal stromal tumors (GISTs), are rare tumors of the digestive tract occurring in one per hundred thousand population. They comprise 0.2% of Gastrointestinal (G.I.) tumors with jejunal GISTs being the rarest subtype [1]. GISTs can present at any age but are most common in middle age, median age being 65 years with only 10-30% of them progressing to malignancy [2-4]. The tumor's location can significantly influence the symptoms, which may range from mild abdominal discomfort to severe conditions such as hematemesis, acute intestinal obstruction, and shock, however, it is often found incidentally during radiological imaging or surgery [5,6]. Typically, these tumors are solitary and do not invade nearby organs, though they can exhibit extra- or intra-luminal growth, or a combination of both [7,8]. In this report, we present a rare case of jejunal GIST that manifested as an acute abdomen with massive gastrointestinal bleeding, managed at a tertiary care center. This case report adheres to the SCARE 2023 guidelines [9].

## 4. Case Report

A 65-year-old diabetic and hypertensive gentleman, presented to the emergency department of our hospital with three-day history of abdominal pain, distension and obstipation with hematemesis and melena for 1 day. There was gradual exacerbation of pain associated with pronounced hematemesis. On examination, the patient was dehydrated, hypotensive, and dyspnoeic with noticeable pallor. The abdomen was distended with a tender palpable mass over the epigastrium extending to the left hypochondrium, and the periumbilical region and melena was evident on rectal examination. After initial assessment and resuscitation, a contrast-enhanced CT scan of the abdomen revealed a large exophytic peripherally thick-walled enhancing mass with necrotic component, showing multiple air-fluid levels in the left upper abdomen, likely arising from the jejunum (Fig.1).

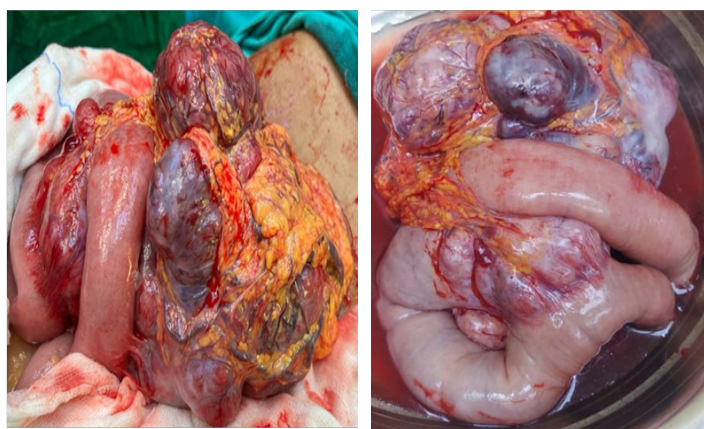
**Fig. 1:** Abdominal CECT-scan: Axial section showing a heterogeneous, exophytic peripherally thick-walled enhancing mass with necrotic component, showing multiple air-fluid levels (Arrow)

# Annals of Clinical and Medical Case Reports



Laboratory investigations showed a hemoglobin (Hb) level of 5.9 mg/dl and minimal inflammatory response. He was shifted to the Intensive care unit (ICU) and received fluid and oxygen supplementation with three blood transfusions raising his Hb to 7.9 mg/dl. Given the diagnostic uncertainty and likelihood of surgical emergency, the patient underwent an exploratory laparotomy with resection anastomosis under general anaesthesia.

Intraoperatively, a large, approximately 20 x 15 x 15 cm exophytic mass, was seen arising from the serosal surface from the antimesenteric border of the jejunum, adhered to the adjacent small bowel loops and transverse colon, with both solid and cystic components. A 12 cm section of bowel was excised sent for histopathology (Fig. 2 a & b). A primary jejuno-jejunal anastomosis was done and the abdomen was closed in layers with an intra-abdominal drain in situ. The postoperative period was uneventful and the patient was discharged in a stable condition on POD 7.



**Fig. 2a:** Peroperative image of the exophytic jejunal mass

**Fig. 2b:** Per operative image of the exophytic jejunal mass after resection with bowel loop

The surgical specimen on Gross examination showed a large grey-brown mass attached to the bowel measuring 20 x 15 x 15 cm with the cut surface showing solid tan-white fleshy areas and cystic spaces filled with blood clots. Microscopy showed a neoplasm arising from the jejunal wall, comprising sheets and fascicles of plump to spindle cells with eosinophilic cytoplasm and moderately pleomorphic elongated nuclei with necrosis. The mitotic rate was up to 6 per 5 mm<sup>2</sup> with a high histological grade – G2. So, the pathological staging according to AJCC 8th edition was – pT4 (Tumour more than 10 cm in greatest dimension) [10] On Immunohistochemistry (IHC), tumor cells expressed DOG1 (Discovered on GIST 1), CD 117 (Protooncogene c kit), and Vimentin whereas Alpha smooth muscle actin (SMA) was patchy positive. PanCK, Desmin, S100, and CD34 were negative. Hence histologically the tumour was diagnosed as a unifocal mixed type Jejunal GIST. The patient underwent a PET scan which did not show any residual disease or metastasis and the tumor was staged as pT4N0M0, Stage IIIB [10]. Since there was no presurgical risk stratification and therapy that was given, Imatinib was started with the dose of 400mg OD. The patient tolerated the treatment well and on 6 monthly follow up did not show any side effects, recurrences, or metastasis.

## 5. Discussion

GISTs are predominantly diagnosed in adults over 40 years of age, with a peak incidence between 60 – 65 years, and have a slight male preponderance [11]. Jejunal GISTs, a rare subtype, often remain asymptomatic until they grow large enough to cause symptoms like pain, obstruction, or gastrointestinal bleeding. Approximately 20% of jejunal GISTs present with palpable masses and obstructive symptoms, and about 25% manifest as GI bleeding, leading to acute or chronic blood loss, including hematemesis, melena, and anemia [12,13]. Large Jejunal GISTs have been known to present with obstructive symptoms as in a case report published by Monib S. et al, a 68-year-old male presented with abdominal mass, pain, and distension and was found to have a Jejunal GIST of size 25 cm in the longest dimension [14]. Azimi B. et al reported a case of jejunal GIST which presented as massive hematemesis with no signs of obstruction but the GIST was of size 6 x 4 x 3.5 cm [15]. Kalita P. et al, published a report on the rare presentation of a 9 x 7 x 6 cm Jejunal GIST, with an extremely uncommon presentation as a right Iliac fossa lump [16]. A retrospective analysis done by Huang Y. et al on the outcomes of resection of GISTs in the duodenum and proximal Jejunum found that of the 27 patients with Jejunal GISTs who were included in the study, 6 out of the 10 were males having tumors of sizes between 15 – 25 cm and belonged to the mean age of 61.6 years [1]. In our case, the patient was a 65-year-old male and had presented with symptoms of both Intestinal obstruction as well as Upper G.I. bleeding and revealed a jejunal GIST of size 20 x 15 x 15 cm.

Although there is a lack of specific diagnostic CT findings for GIST tumors, they typically appear as a heterogenous mass with areas of necrosis and hemorrhage whereas viable tumour areas show contrast enhancement in the periphery [17] which was also seen in our case. GISTs are identified

# Annals of Clinical and Medical Case Reports

microscopically as three different patterns – Spindle cell type (60 – 70%), epithelioid type (30 – 40%), and mixed type (10 – 20%). In our case, GIST was of spindle cell type. However, it is hard to differentiate these lesions from other subepithelial tumors like leiomyoma, leiomyosarcoma, GI cysts, and lipomas by microscopic evaluation and an IHC study is necessary for differentiation [18,19].

The possible root cause of GIST is the genetic mutation with almost 95 % of cases being linked to the mutation in the KIT gene, whereas only 3–5 % were associated with mutations in the PDGFR $\alpha$  gene [20]. The KIT gene, also known as the c-kit gene encodes protooncogene c kit or CD117, the overexpression of which leads to neoplasia [21]. Moreover, DOG-1 protein was identified as a highly sensitive and specific marker especially in CD117-negative tumours. It is a calcium-regulated chloride channel protein that is expressed on the GIST cell membrane. Most GISTs are strongly positive for CD 117 along with CD34 (70–90%), SMA (20–30%), S-100 (8–10%), and desmin (2–4%) [22]. In our case, the tumour was positive for DOG1, CD 117 whereas SMA was patchy positive. PanCK, Desmin, S100, and CD34 were negative. Complete surgical resection with a 1 cm margin is the standard treatment for localized GISTs, though metastatic relapse occurs in about 40% of cases [23]. Imatinib mesylate, a protein tyrosine kinase inhibitor, is the first and only effective drug for the treatment of GIST at present. Studies have shown that adjuvant imatinib improves relapse-free survival, with three years of treatment offering better outcomes than one year in high-risk patients. Accordingly, our patient was started on imatinib in consultation with an oncologist [24–26].

## 6. Conclusion

Jejunal GISTs, though a rare subtype of small intestinal tumors, can lead to life-threatening complications. Their presentation, often as upper GI bleeding, can result in misdiagnosis, delaying crucial surgical intervention. While CT scans are useful for identifying GISTs, definitive diagnosis relies on histopathology, with IHC markers playing a critical role. The management of GISTs extends beyond surgery, with chemotherapy, particularly as adjuvant and neoadjuvant therapy, becoming essential. Prognosis depends on tumor size and mitotic activity, making complete resection vital for improved outcomes.

## References

- Huang Y, Chen G, Lin L, Jin X, Kang M, Zhang Y, et al. Resection of GIST in the duodenum and proximal jejunum: A retrospective analysis of outcomes. *Eur J Surg Oncol*. 2019 Oct;45(10):1950-1956.
- Choi H. Response evaluation of gastrointestinal stromal tumors. *Oncologist*. 2008;13 Suppl 2:4-7.
- Nishida T, Goto O, Raut CP, Yahagi N. Diagnostic and treatment strategy for small gastrointestinal stromal tumors. *Cancer* 2016; 122: 3110-8.
- Stotz M, Liegl-Atzwanger B, Posch F, Mrcic E, Thalhammer M, Stojakovic T, et al. Blood-based biomarkers are associated with disease recurrence and survival in gastrointestinal stroma tumor patients after surgical resection. *PloS One* 2016; 11: e0159448.
- Miettinen M, Lasota J. Gastrointestinal stromal tumors--definition, clinical, histological, immunohistochemical, and molecular genetic features and differential diagnosis. *Virchows Arch*. 2001 Jan;438(1):1-12.
- Gerrish ST, Smith JW. Gastrointestinal stromal tumors-diagnosis and management: a brief review. *Ochsner J*. 2008 Winter;8(4):197-204.
- Kim SH, Lee MS, Cho BS, et al. Gastrointestinal stromal tumor of the stomach presenting as multilobular with diffuse calcifications. *J Gastric Cancer* 2016; 16: 58-62.
- Maeda E, Fujiwara M, Suto H, et al. Multiple gastric gastrointestinal stromal tumors treated by laparoscopic-endoscopic cooperative surgery: a case report. *Asian J Endoscop Surg* 2016; 9: 336-9.
- C. Sohrabi, G. Mathew, N. Maria, A. Kerwan, T. Franchi, R.A. Agha, Collaborators. The SCARE 2023 guideline: updating consensus surgical Case Report (SCARE) guidelines, *Int. J. Surg. (Lond., Engl.)*. 2023 May 1;109(5):1136-1140.
- American Joint Committee on Cancer. *Gastrointestinal Stromal Tumor*. Amin MB, Edge S, Greene F, Byrd DR, Brookland RK, et al, eds. *AJCC Cancer Staging Manual*. 8th edition. New York, NY: Springer; 2016. 226-232
- Rammohan A, Sathyanesan J, Rajendran K, Pitchaimuthu A, Perumal SK, Srinivasan U, et al. A gist of gastrointestinal stromal tumors: A review. *World J Gastrointest Oncol*. 2013 Jun 15;5(6):102-12.
- Sankey RE, Maatouk M, Mahmood A, Raja M. Case Report: Jejunal gastrointestinal stromal tumour, a rare tumour, with a challenging diagnosis and a successful treatment. *J Surg Case Rep*. 2015 May 1;2015(5):rjv050.
- Caterino S, Lorenzon L, Petrucciani N, Iannicelli E, Pillozzi E, Romiti A, et al. Gastrointestinal stromal tumors: correlation between symptoms at presentation, tumor location and prognostic factors in 47 consecutive patients. *World J Surg Oncol*. 2011 Feb 1;9:13.
- Monib S, Habashy HF. Football Size Jejunal Gastrointestinal Stromal Tumour. *Cureus*. 2020 Dec 5;12(12):e11913.
- Azimi B, Shahrabaf MA, Iranshahi M, Parsaeian F. A case of jejunal GIST revealed by hematemesi: Unusual situation. *Int J Surg Case Rep*. 2022 May;94:107146.
- Kalita, Pranjit & Gupta, Arnab & Sengupta, Piyas & Bhattacharyya, Samir. A rare presentation of jejunal GIST: A case report. *Indian Journal of Case Reports*. 2024; 10: 15-18.
- Da Ronch T, Modesto A, Bazzocchi M. Gastrointestinal stromal tumour: spiral computed tomography features and pathologic correlation. *Radiol Med*. 2006 Aug;111(5):661-73.
- Foo WC, Liegl-Atzwanger B, Lazar AJ. Pathology of gastrointestinal stromal tumors. *Clin Med Insights Pathol*. 2012;5:23-33.
- Graadt van Roggen JF, van Velthuysen ML, Hogendoorn PC. The histopathological differential diagnosis of gastrointestinal stromal tumours. *J Clin Pathol*. 2001 Feb;54(2):96-102.
- Tan CB, Zhi W, Shahzad G, Mustacchia P. Gastrointestinal stromal

# Annals of Clinical and Medical Case Reports

---

- tumors: a review of case reports, diagnosis, treatment, and future directions. *ISRN Gastroenterol.* 2012;2012:595968.
21. Huret JL, Ahmad M, Arsaban M, Bernheim A, Cigna J, Desangles F, et al. Atlas of genetics and cytogenetics in oncology and haematology in 2013. *Nucleic Acids Res.* 2012 Nov 17;41(D1):D920-D924.
  22. Khuri S, Gilshtein H, Darawshy AA, Bahouth H, Kluger Y. Primary Small Bowel GIST Presenting as a Life-Threatening Emergency: A Report of Two Cases. *Case Rep Surg.* 2017;2017:1814254.
  23. Joensuu H, Vehtari A, Riihimäki J, Nishida T, Steigen SE, Brabec P, et al. Risk of recurrence of gastrointestinal stromal tumour after surgery: an analysis of pooled population-based cohorts. *Lancet Oncol* 2012; 13: 265-274.
  24. Dematteo RP, Ballman KV, Antonescu CR, Maki RG, Pisters PWT, Demetri GD, et al. Adjuvant imatinib mesylate after resection of localised, primary gastrointestinal stromal tumour: a randomised, double-blind, placebo-controlled trial. *Lancet* 2009; 373: 1097-1104.
  25. Joensuu H, Eriksson M, Sundby Hall K, Hartmann JT, Pink D, Schütte J, et al. One vs three years of adjuvant imatinib for operable gastrointestinal stromal tumor: a randomized trial. *JAMA* 2012; 307: 1265-1272.
  26. Serrano C, Martín-Broto J, Asencio-Pascual JM, López-Guerrero JA, Rubió-Casadevall J, Bagué S, et al. 2023 GEIS Guidelines for gastrointestinal stromal tumors. *Therapeutic Advances in Medical Oncology.* 2023 Aug 24; 15:17588359231192388.